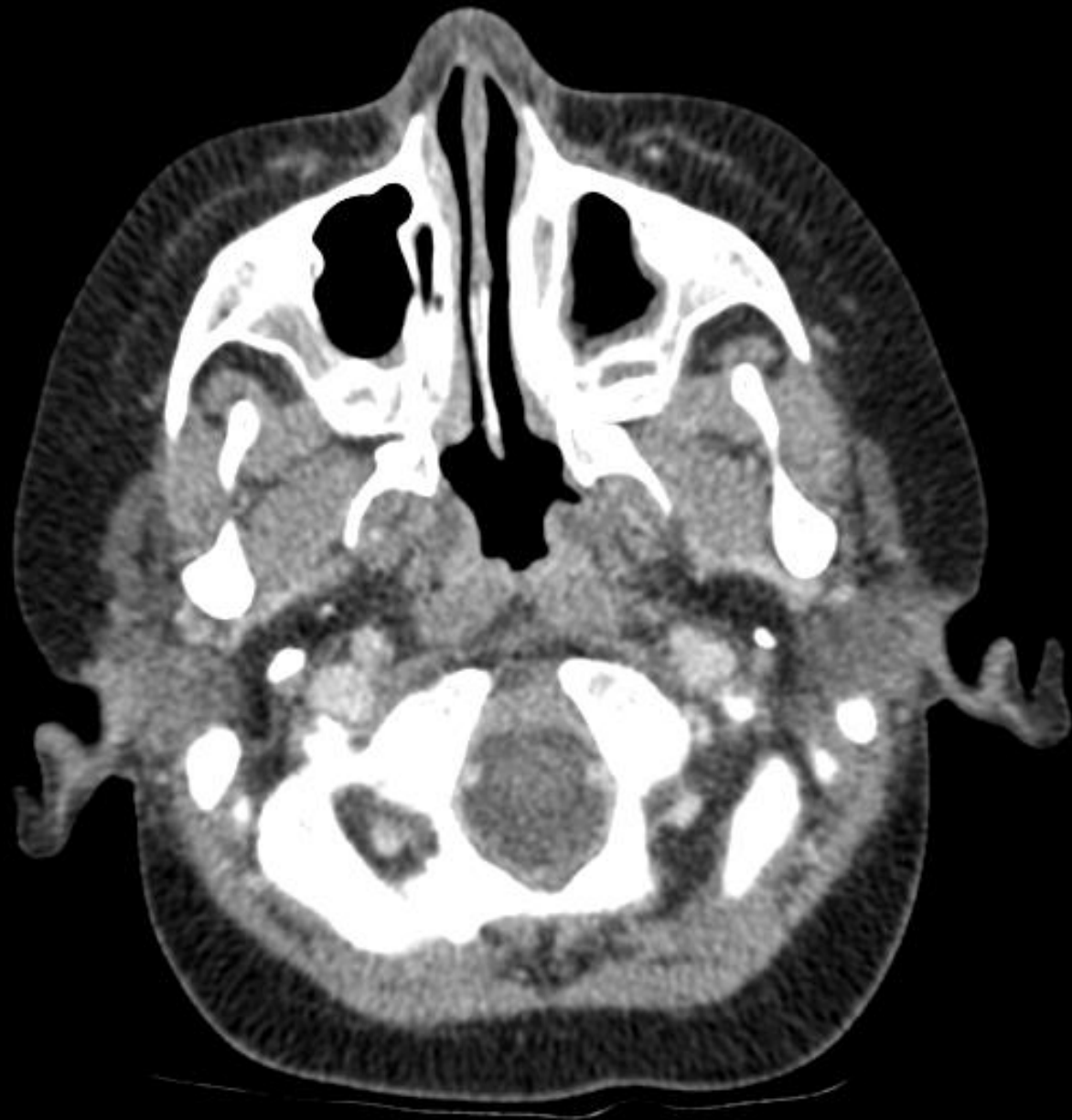
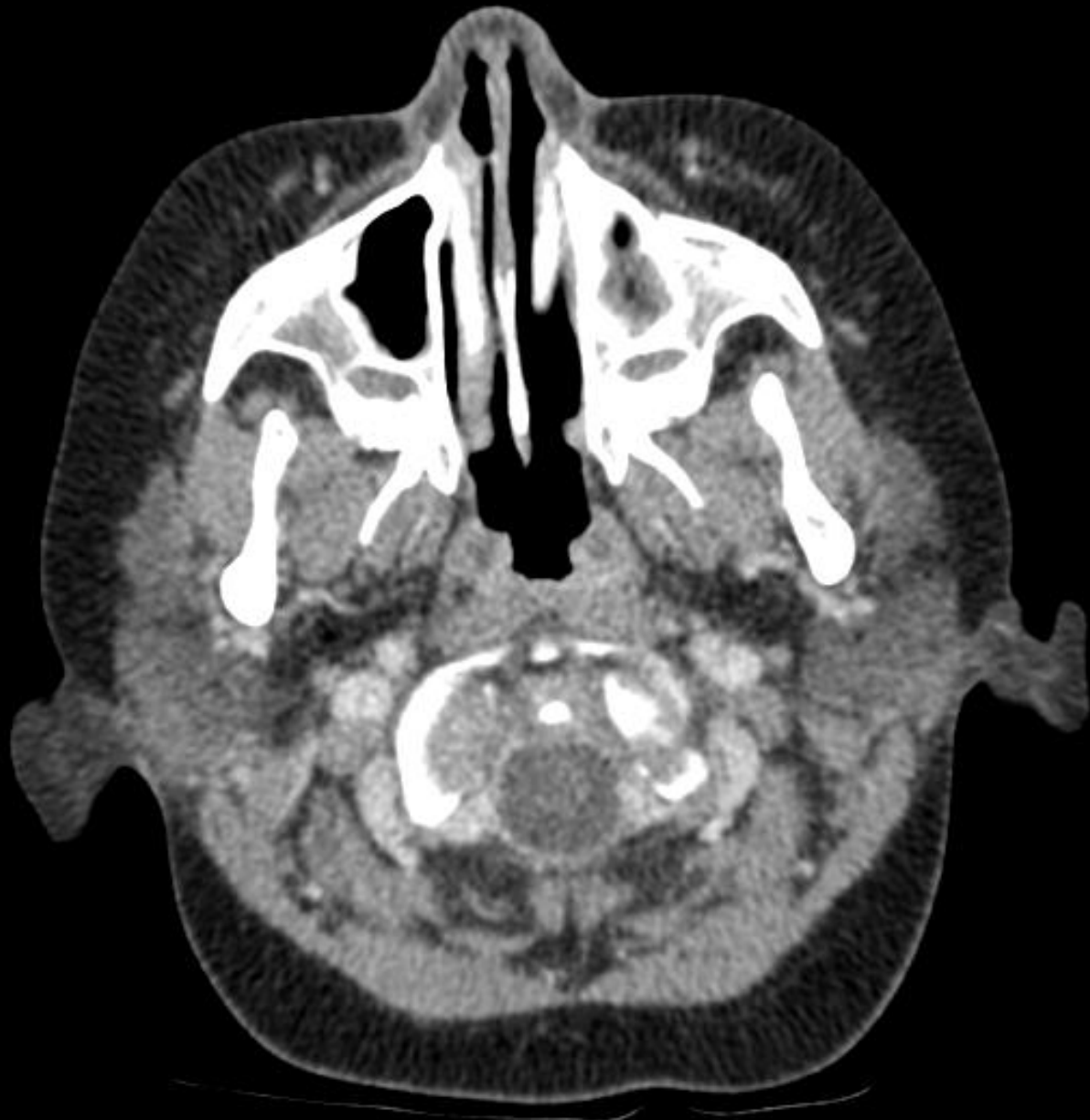
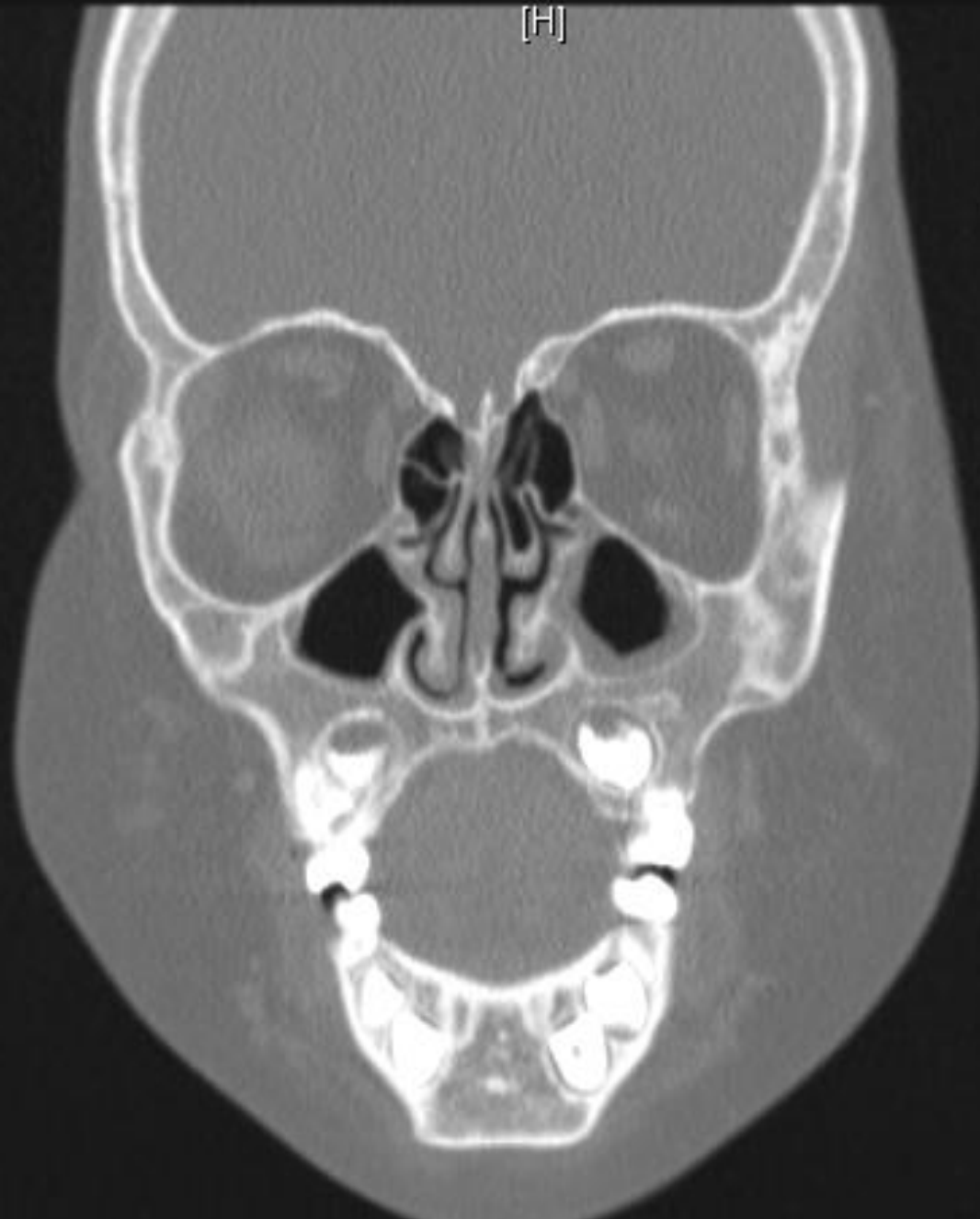


CT, 1/26/2012

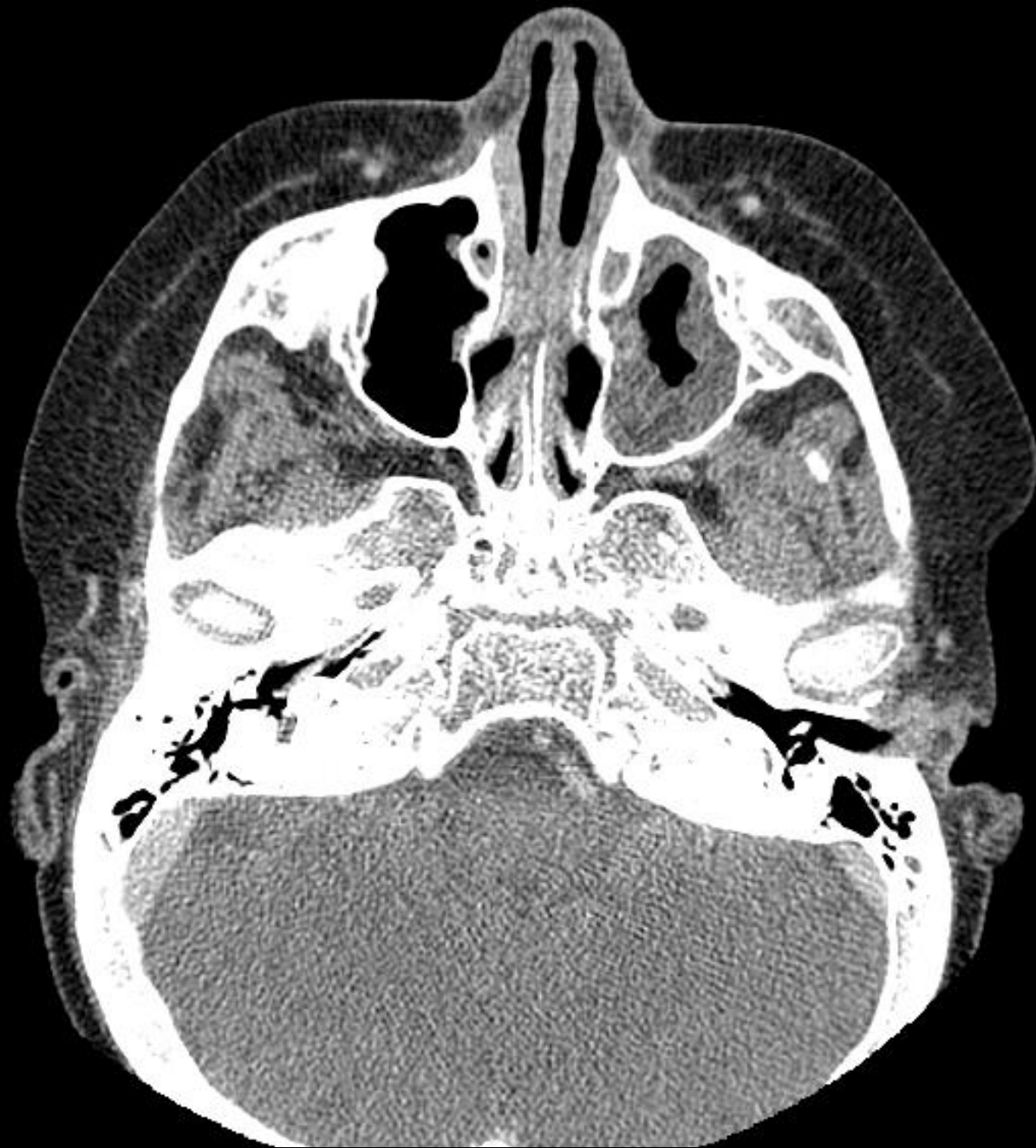

CT, 1/26/2012

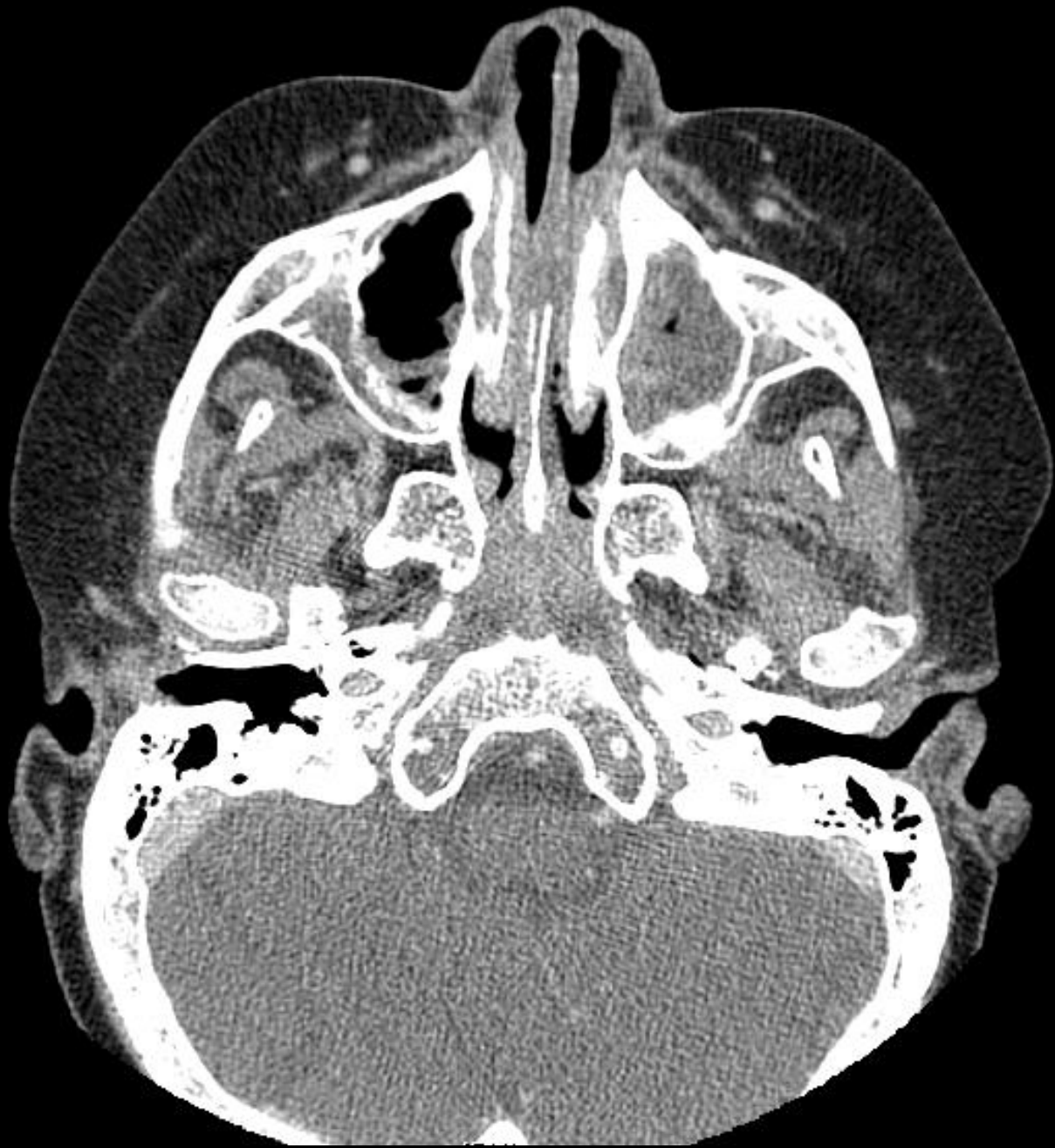
[H]



CT, soft tissue window, 1/26/2012

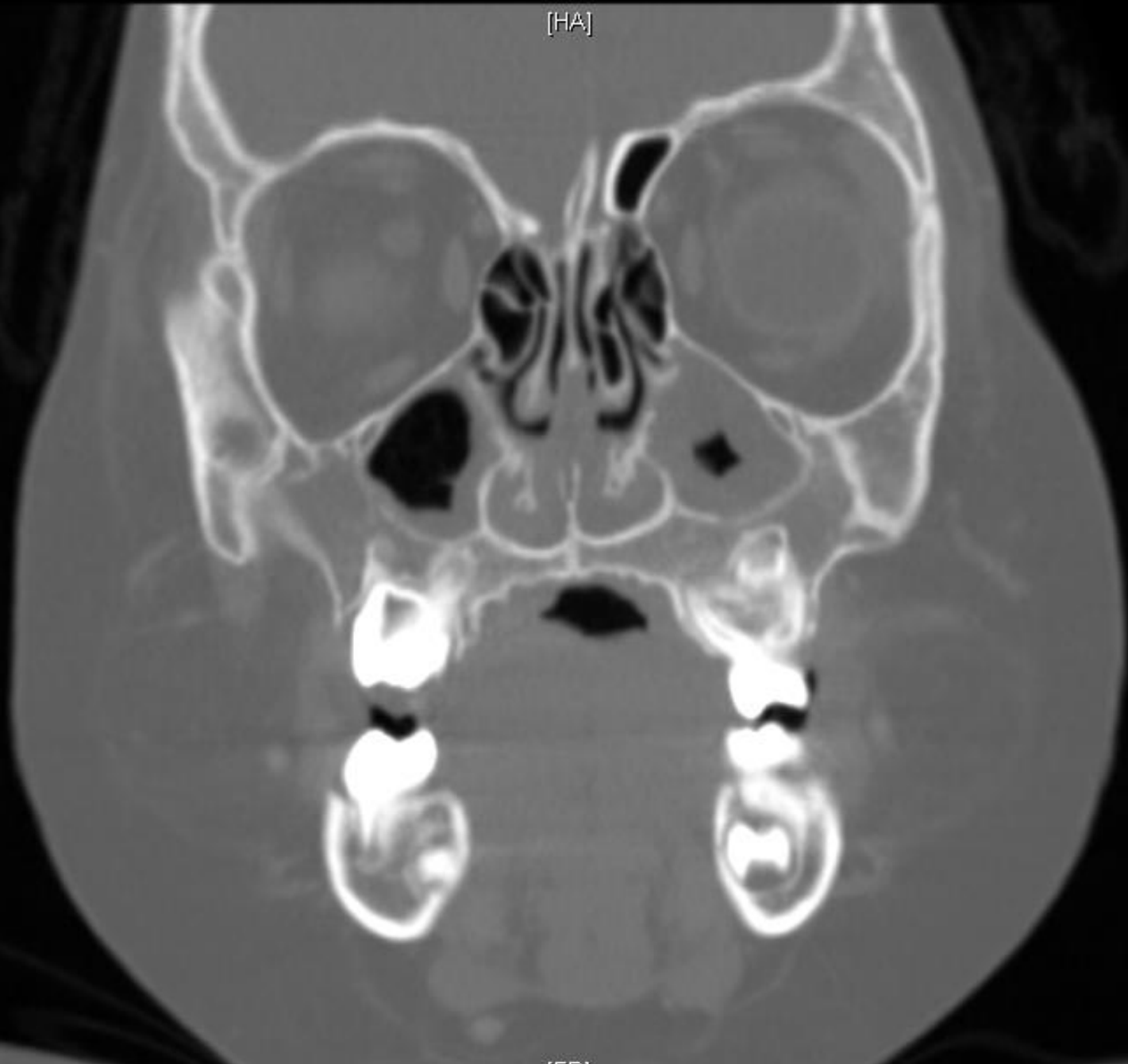


CT, 2/5/2012



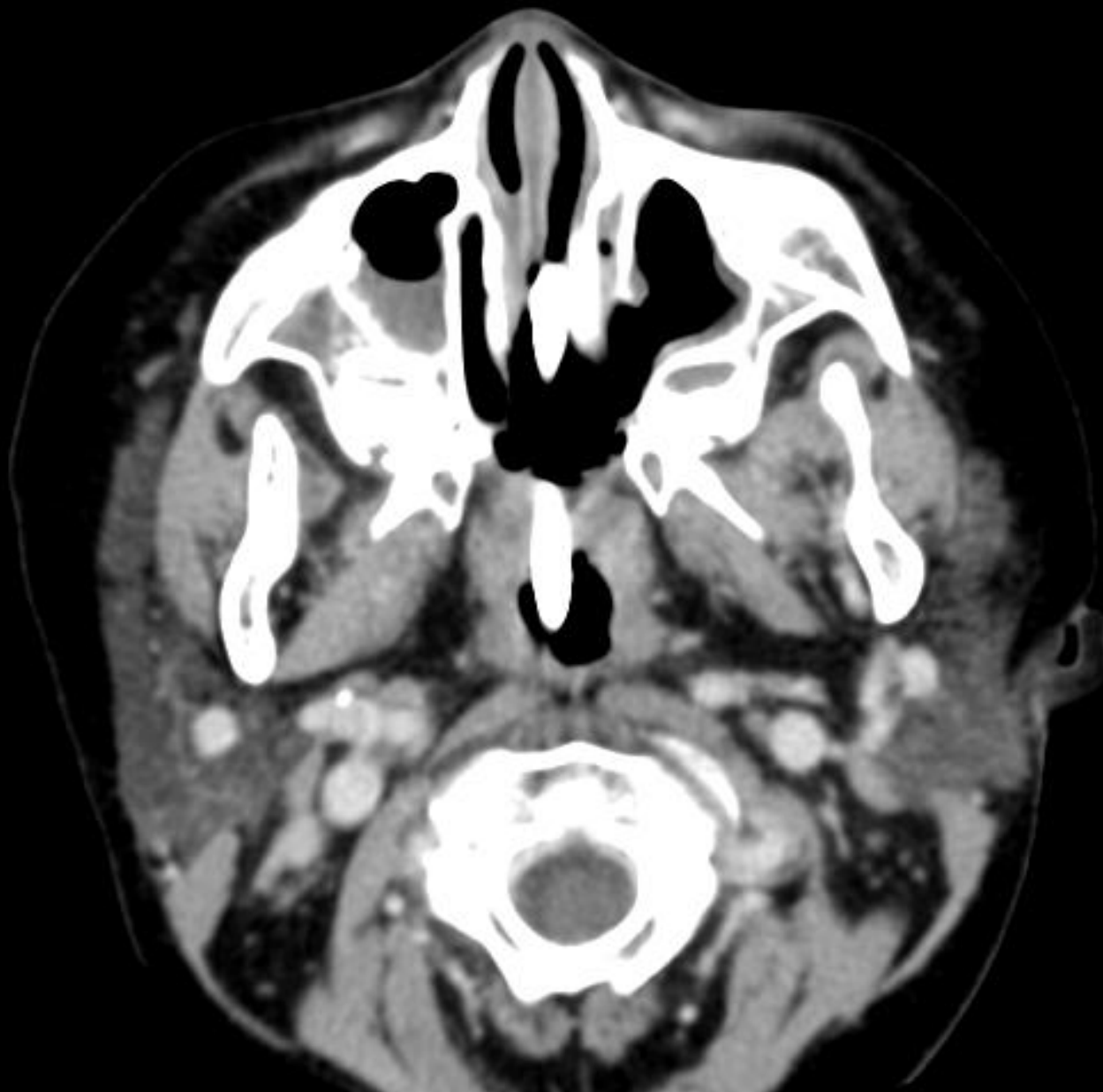CT, 2/5/2012

[HA]

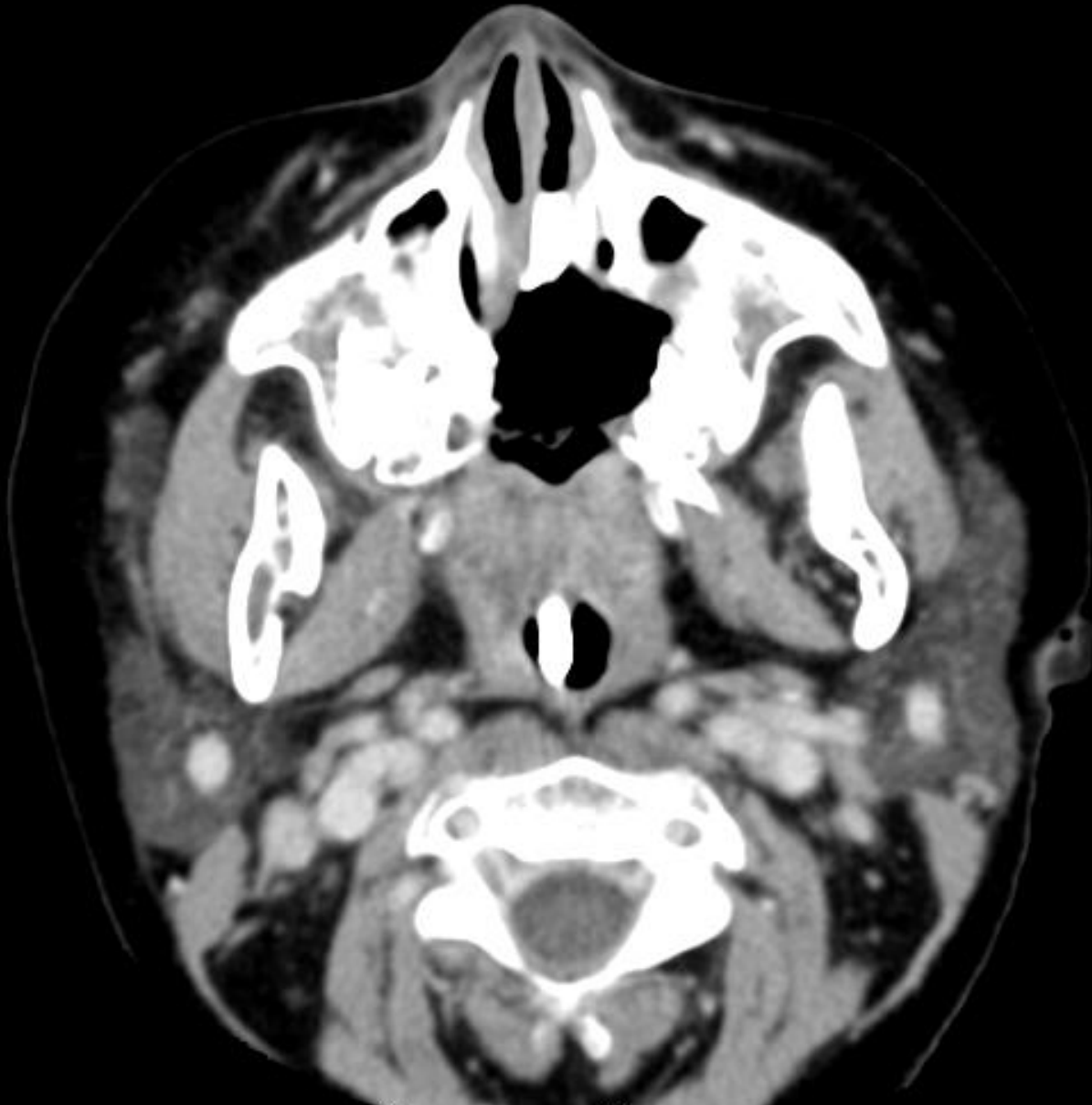


[551]

CT, soft tissue window, 2/5/2012



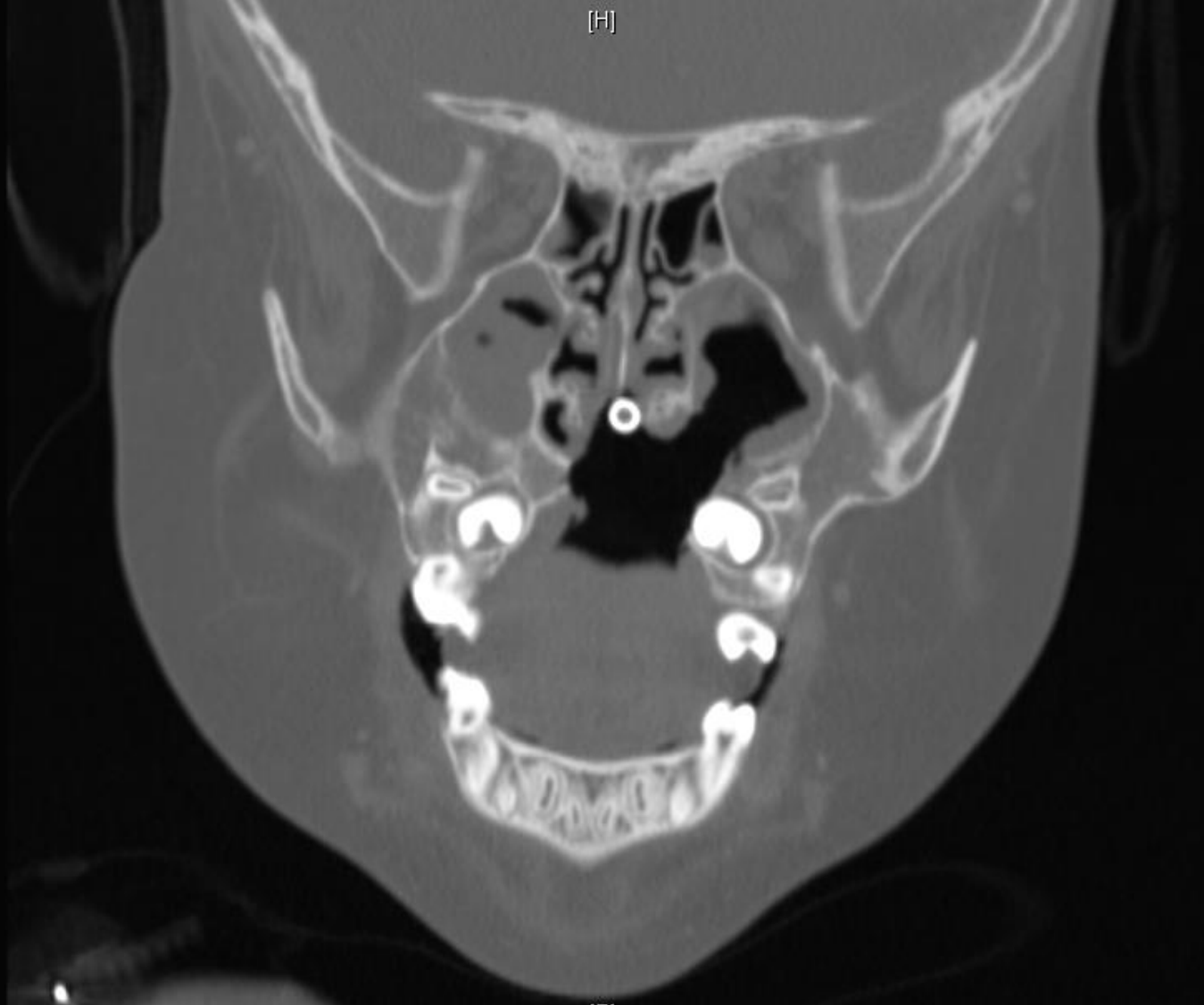
CT, 2/11/2012



CT, 2/11/2012

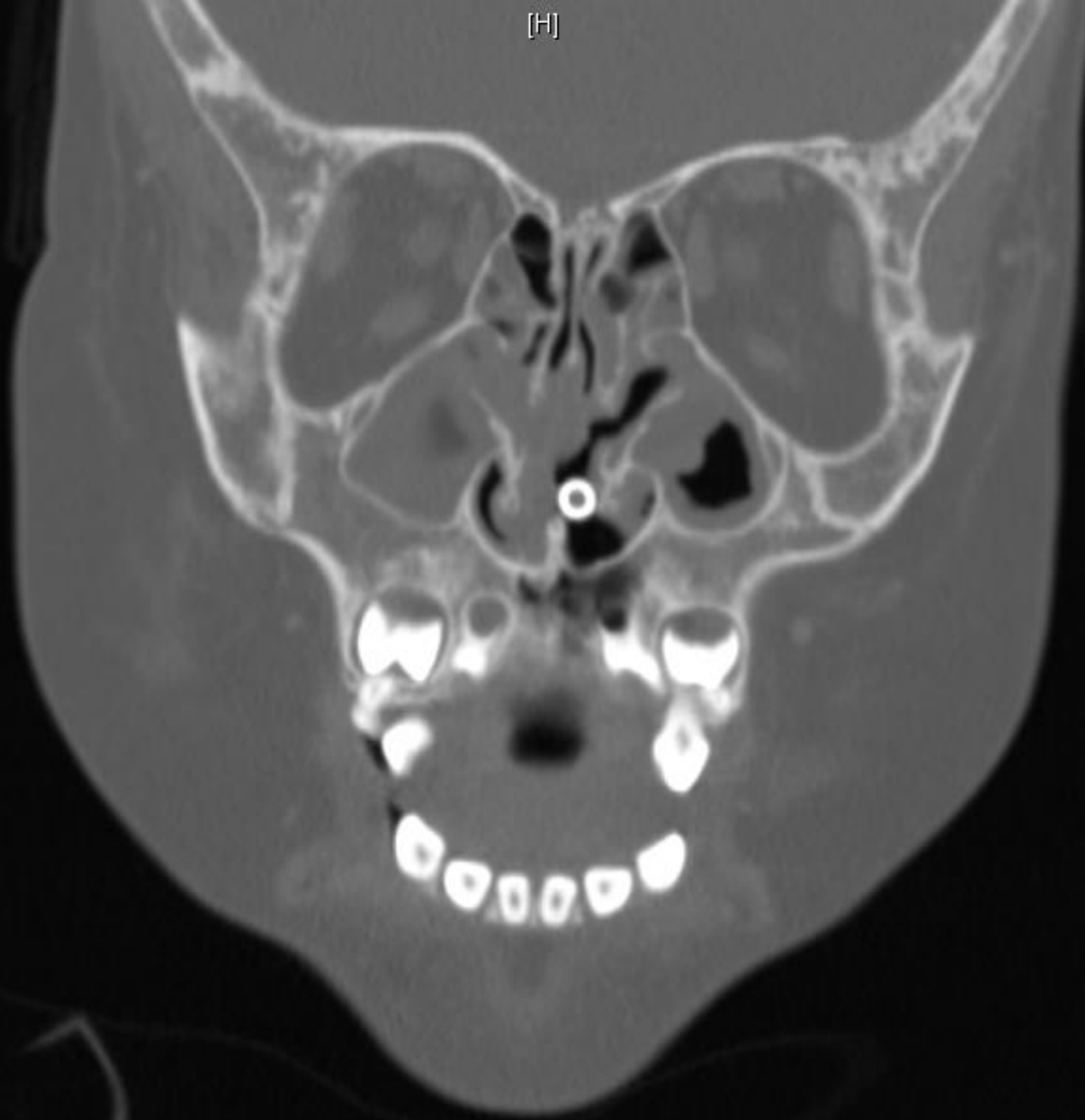


[H]



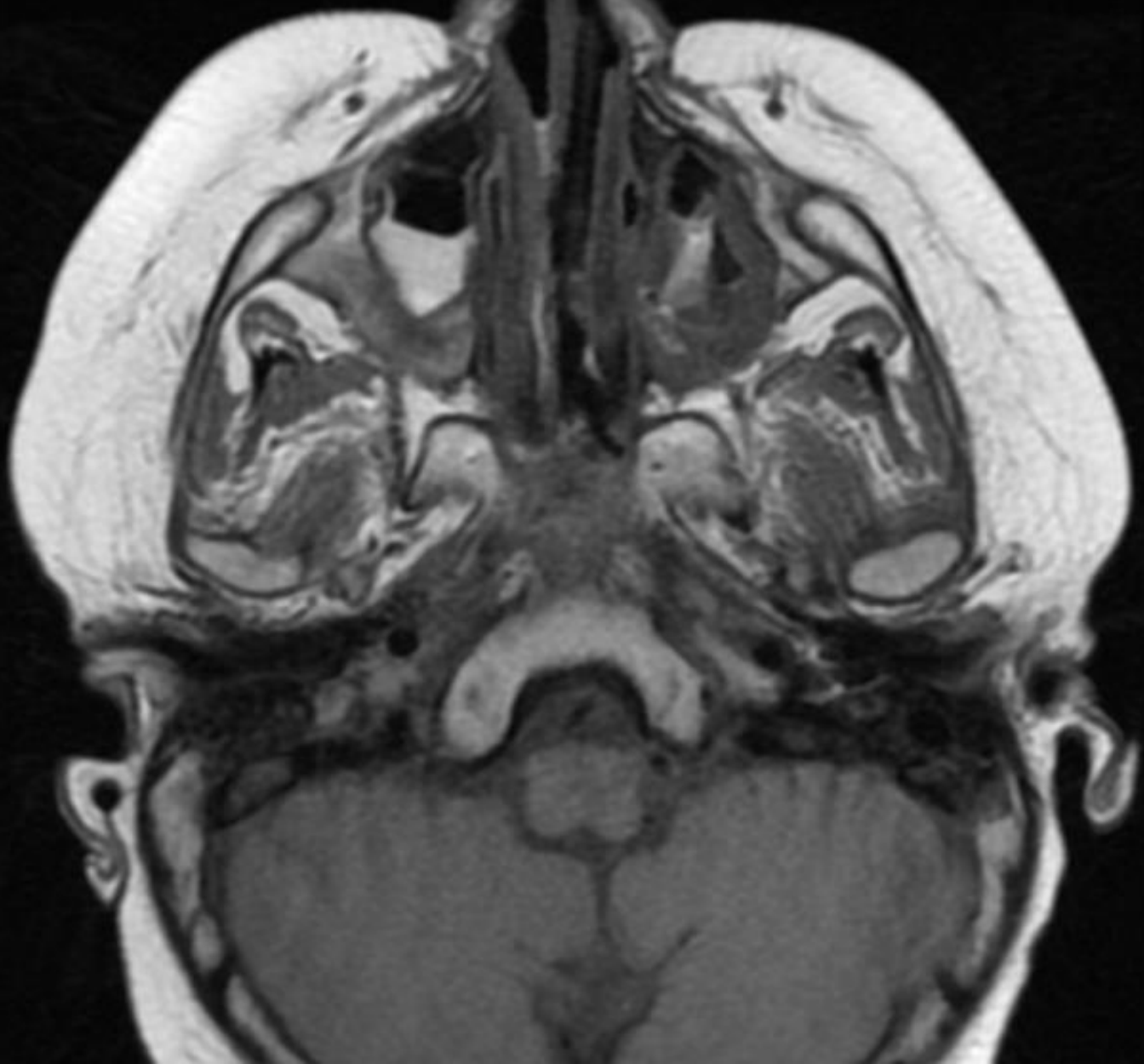
CT, soft tissue window, 2/11/2012

[H]



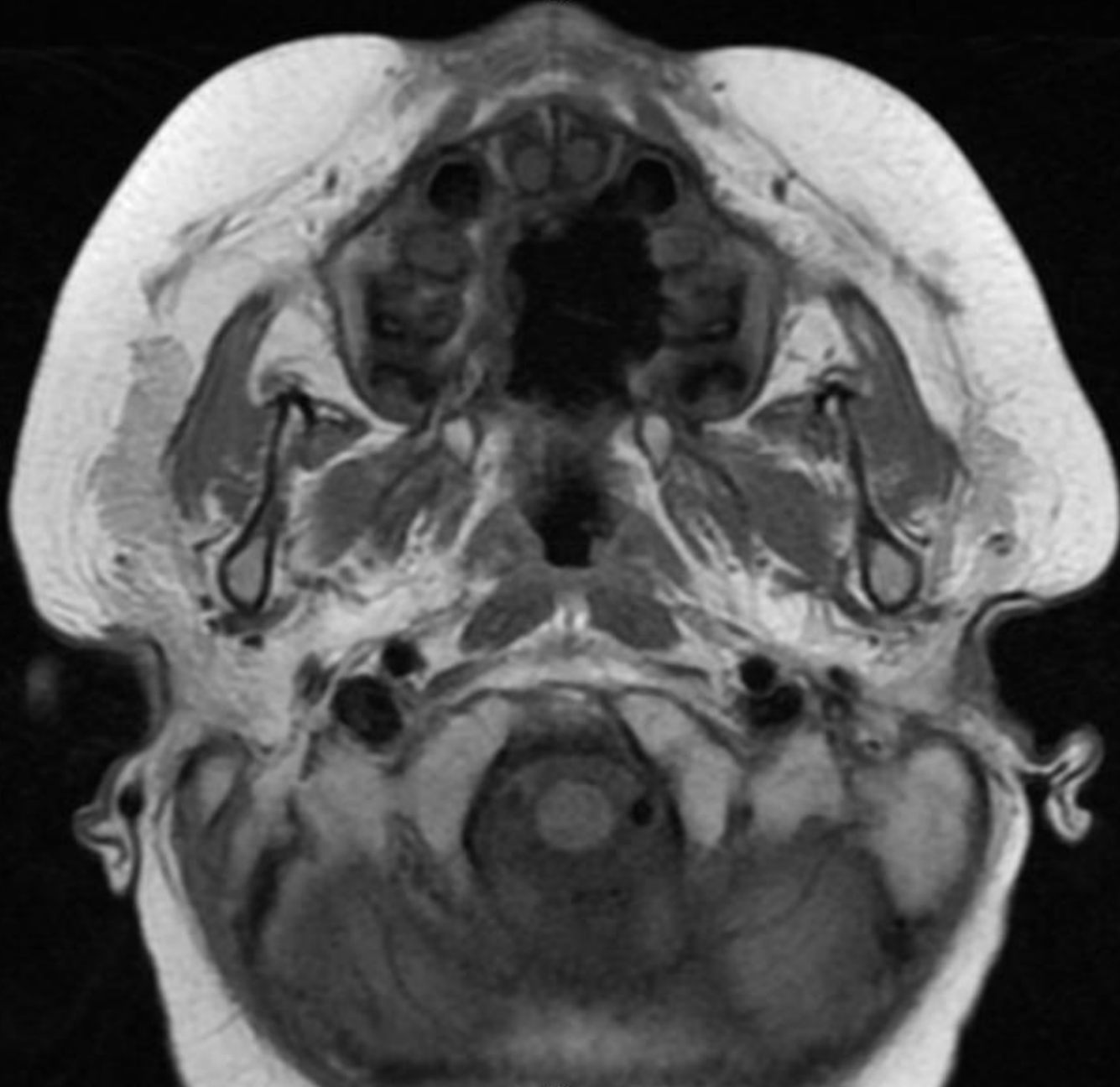
CT, soft tissue window, 2/11/2012

[A]



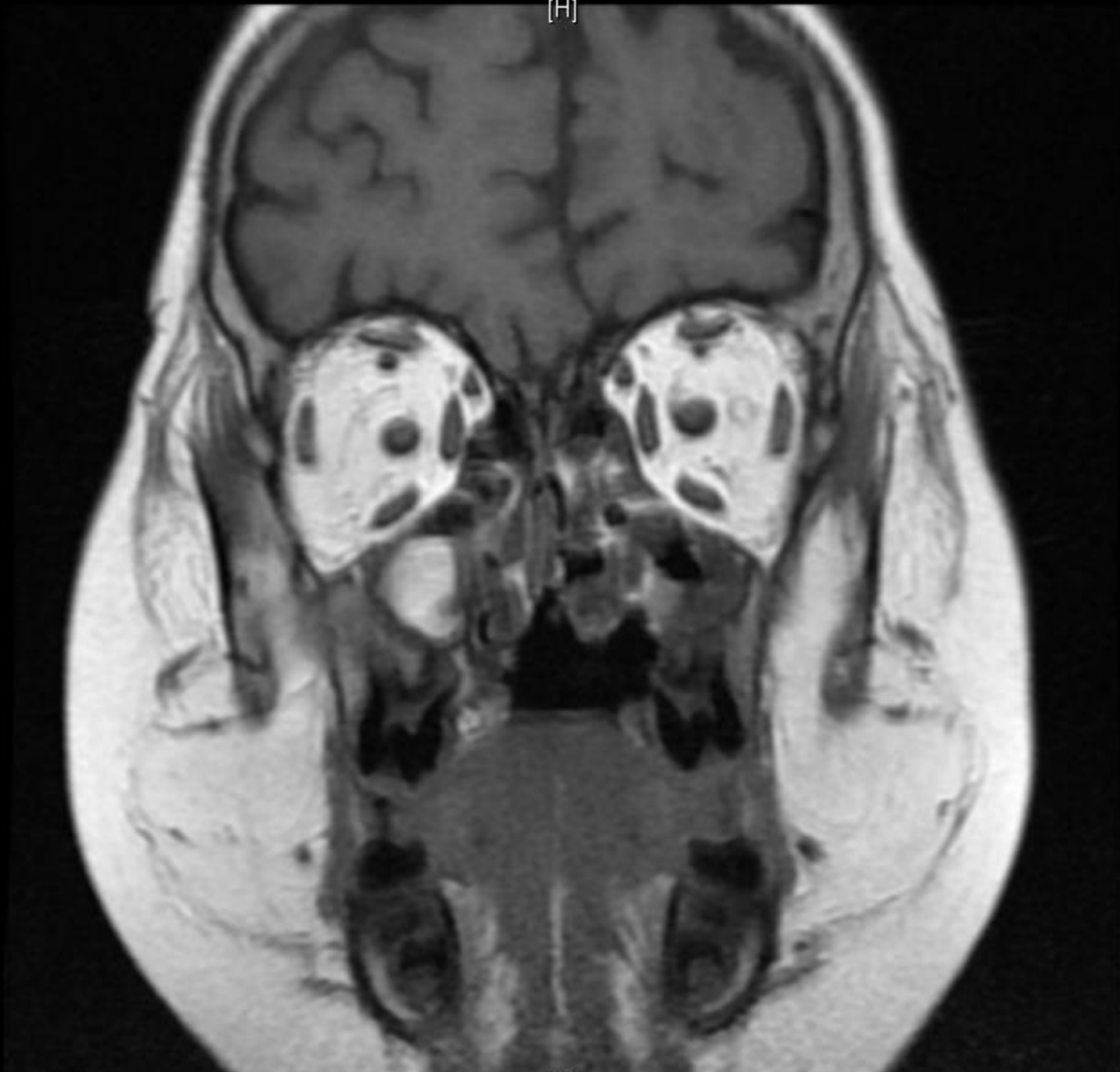
MR (T1), 2/15/2012

[A]

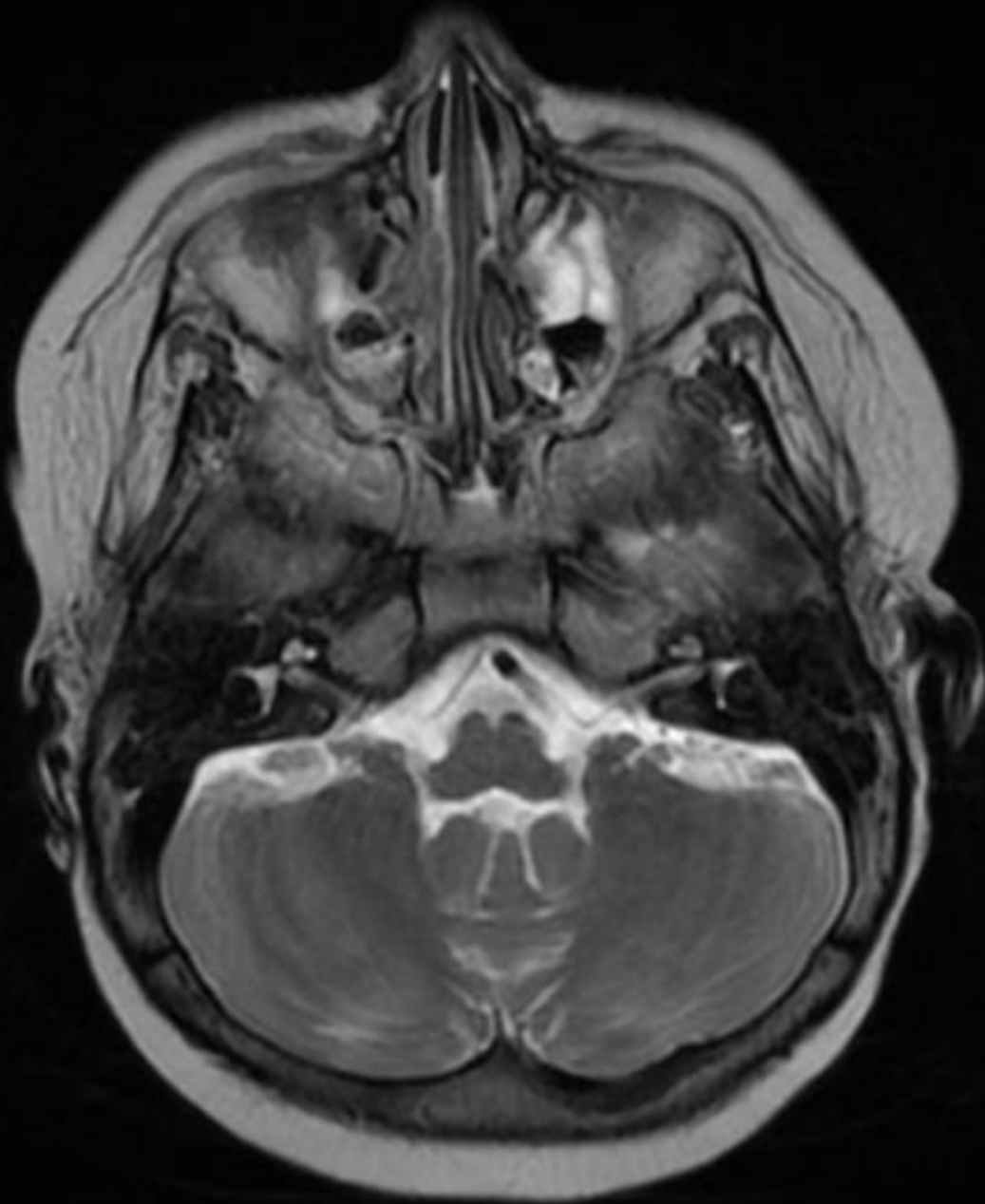


MR (T1), 2/15/2012

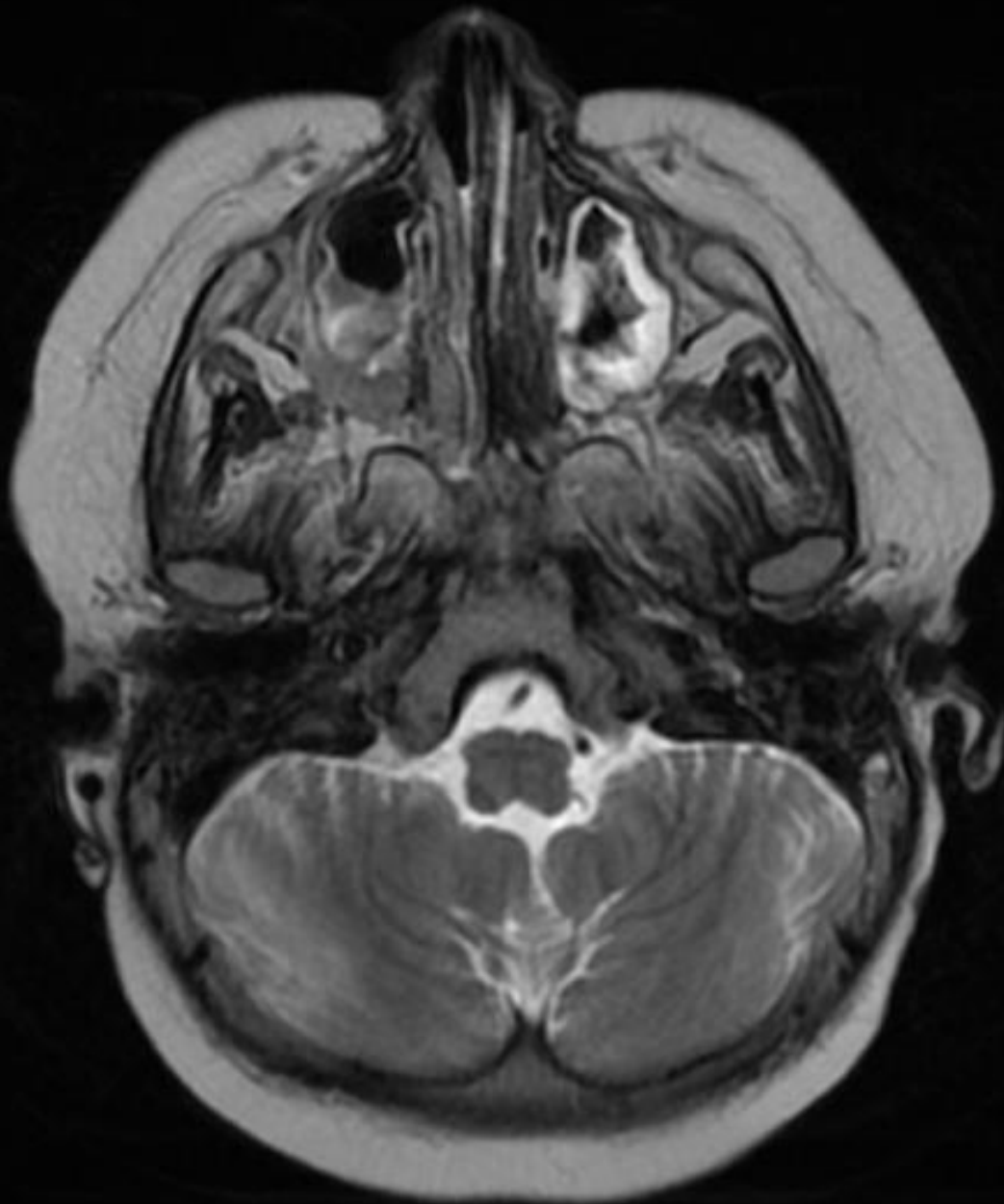
[H]



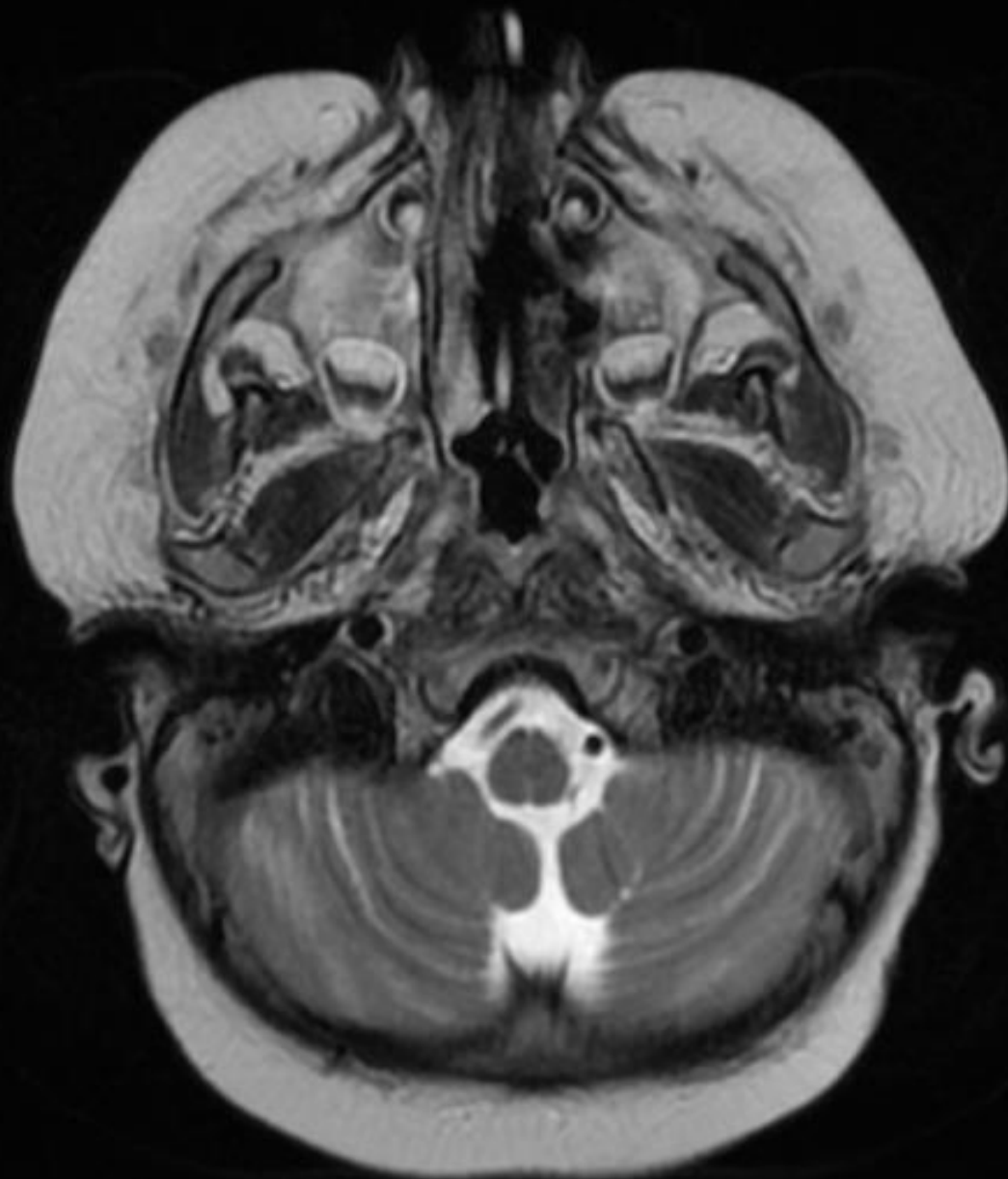
MR (T1), 2/15/2012



MR (T2), 2/15/2012



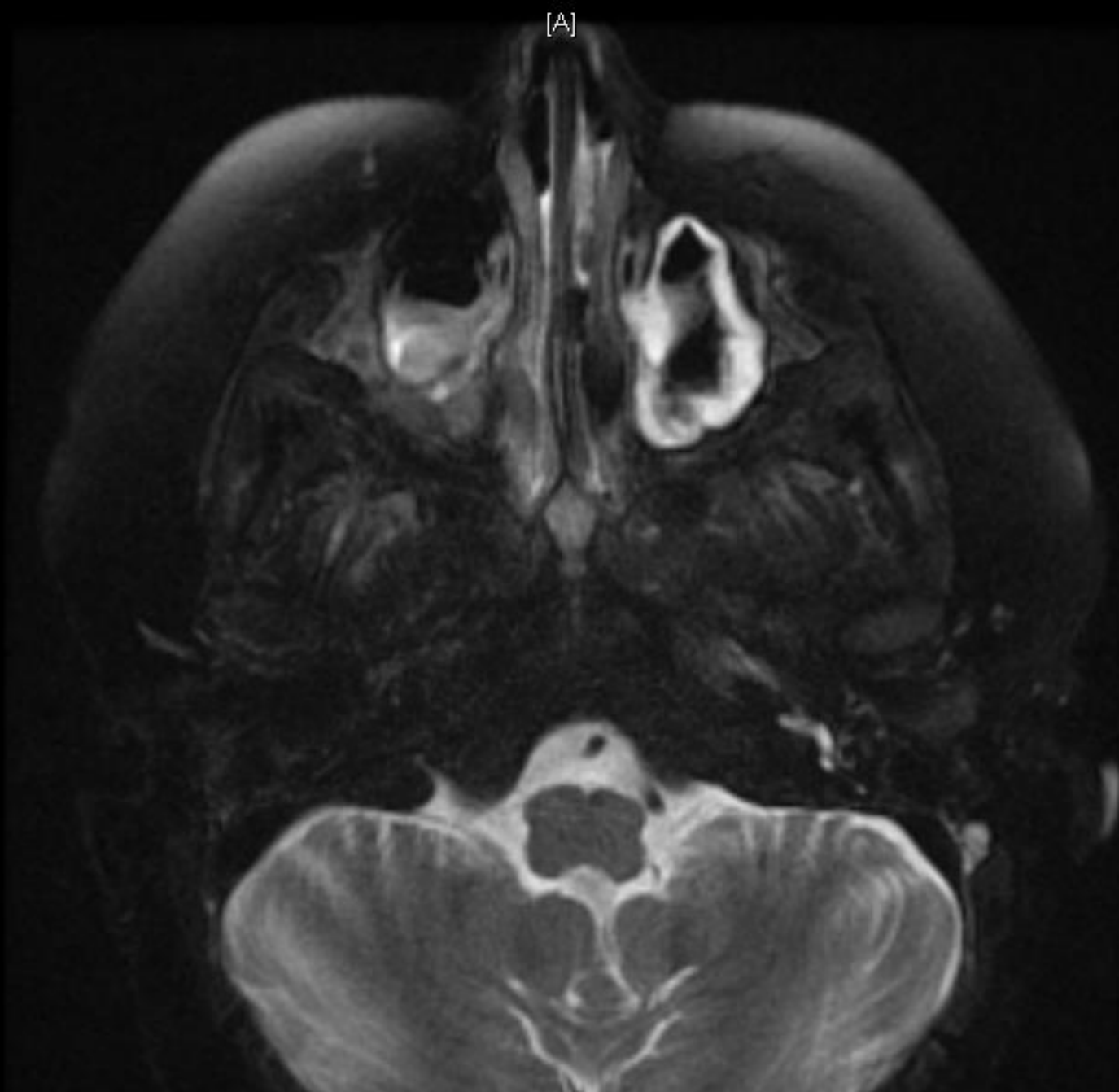
MR (T2), 2/15/2012



MR (T2), 2/11/2012

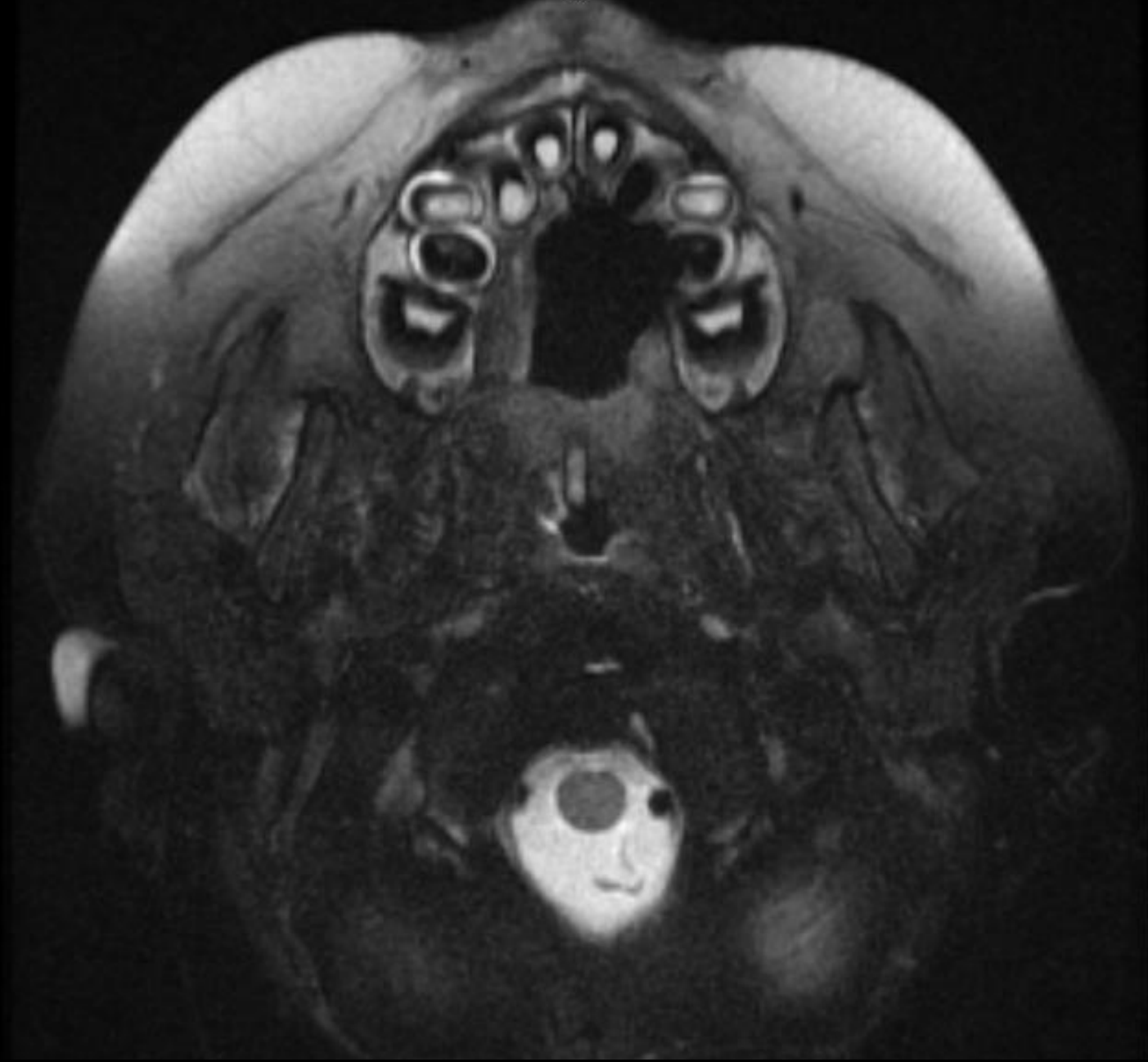


[A]

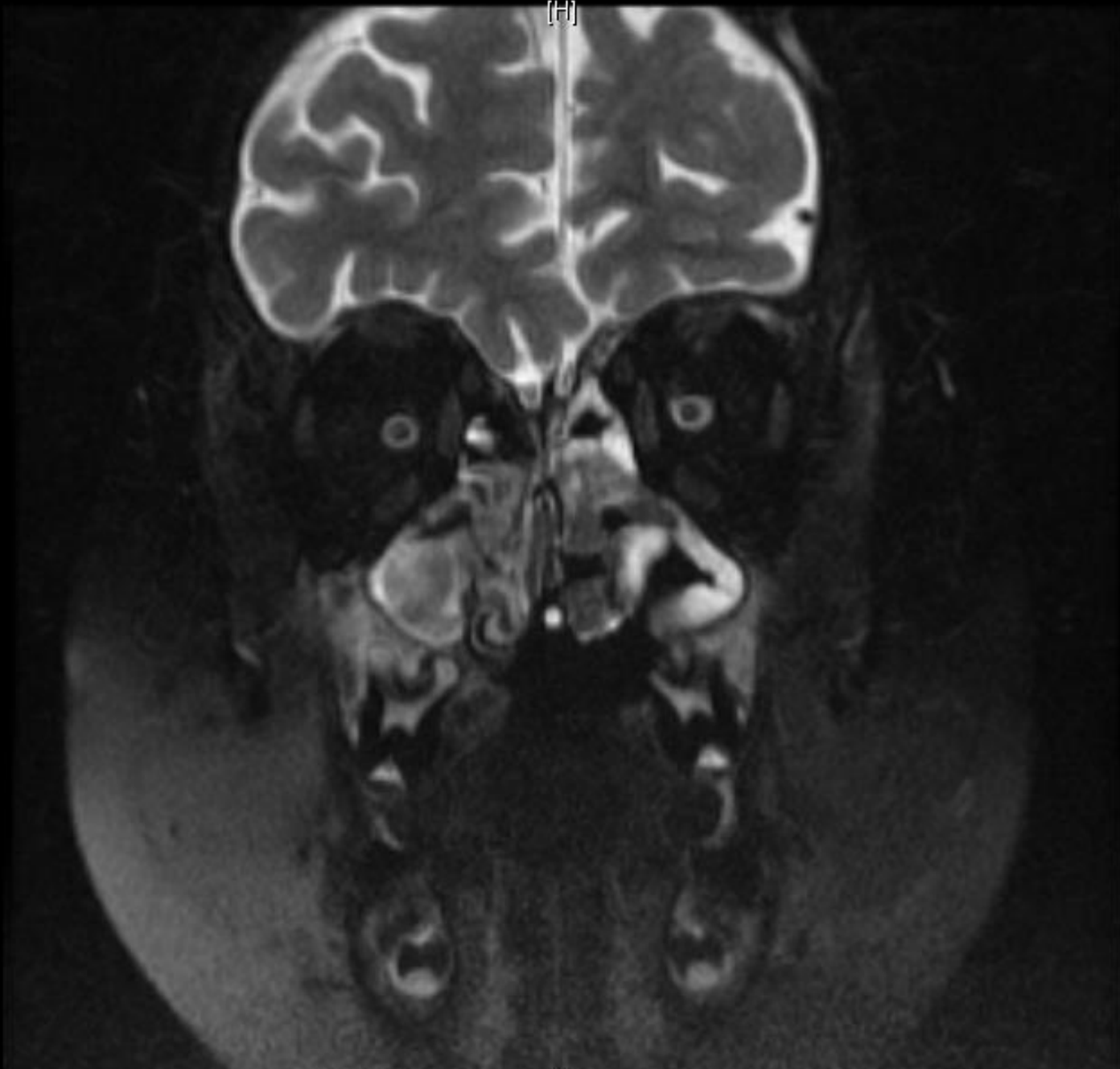


MR (T2 FAT SAT), 2/11/2012

[A]

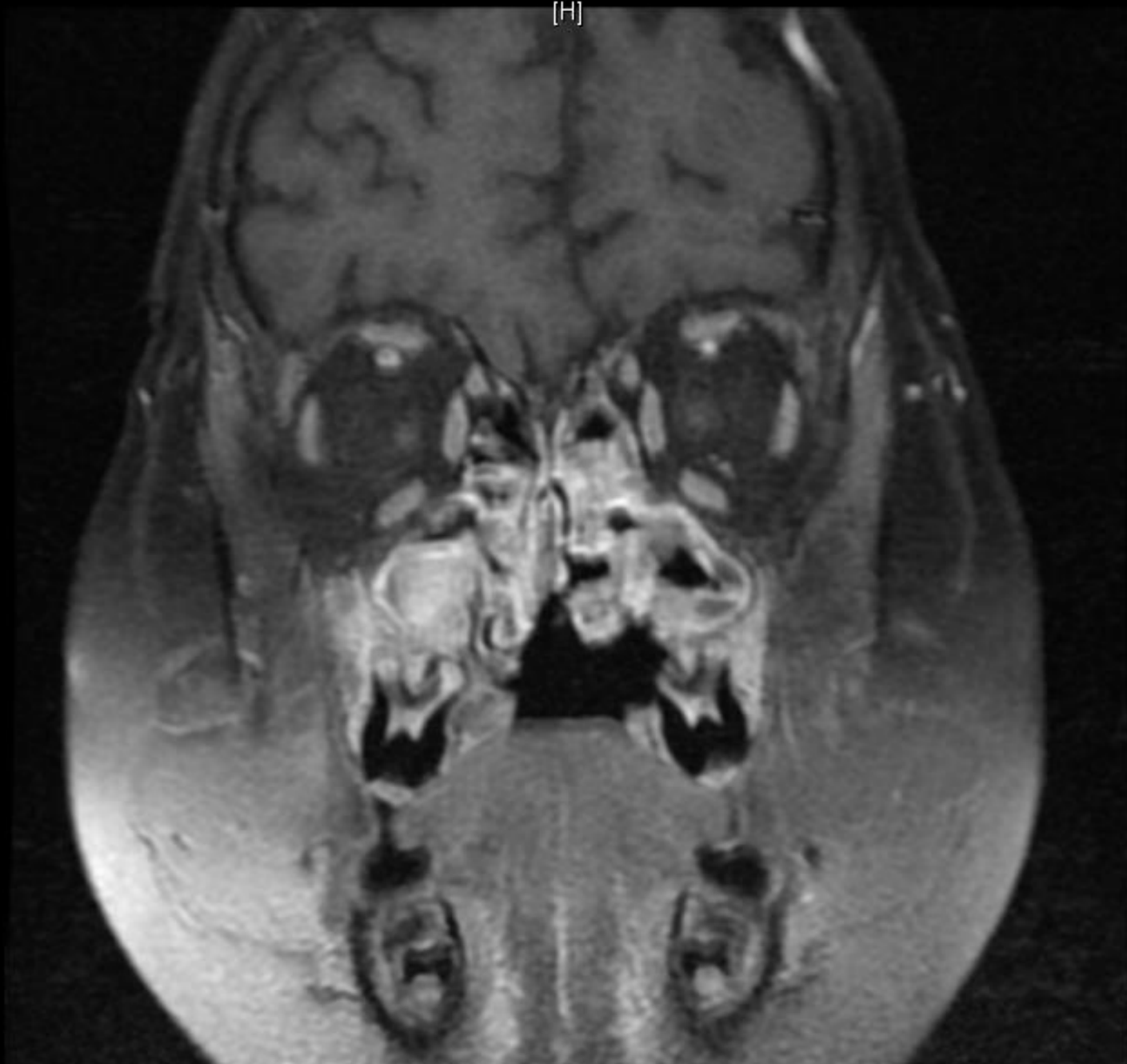


MR (T2 FAT SAT), 2/11/2012



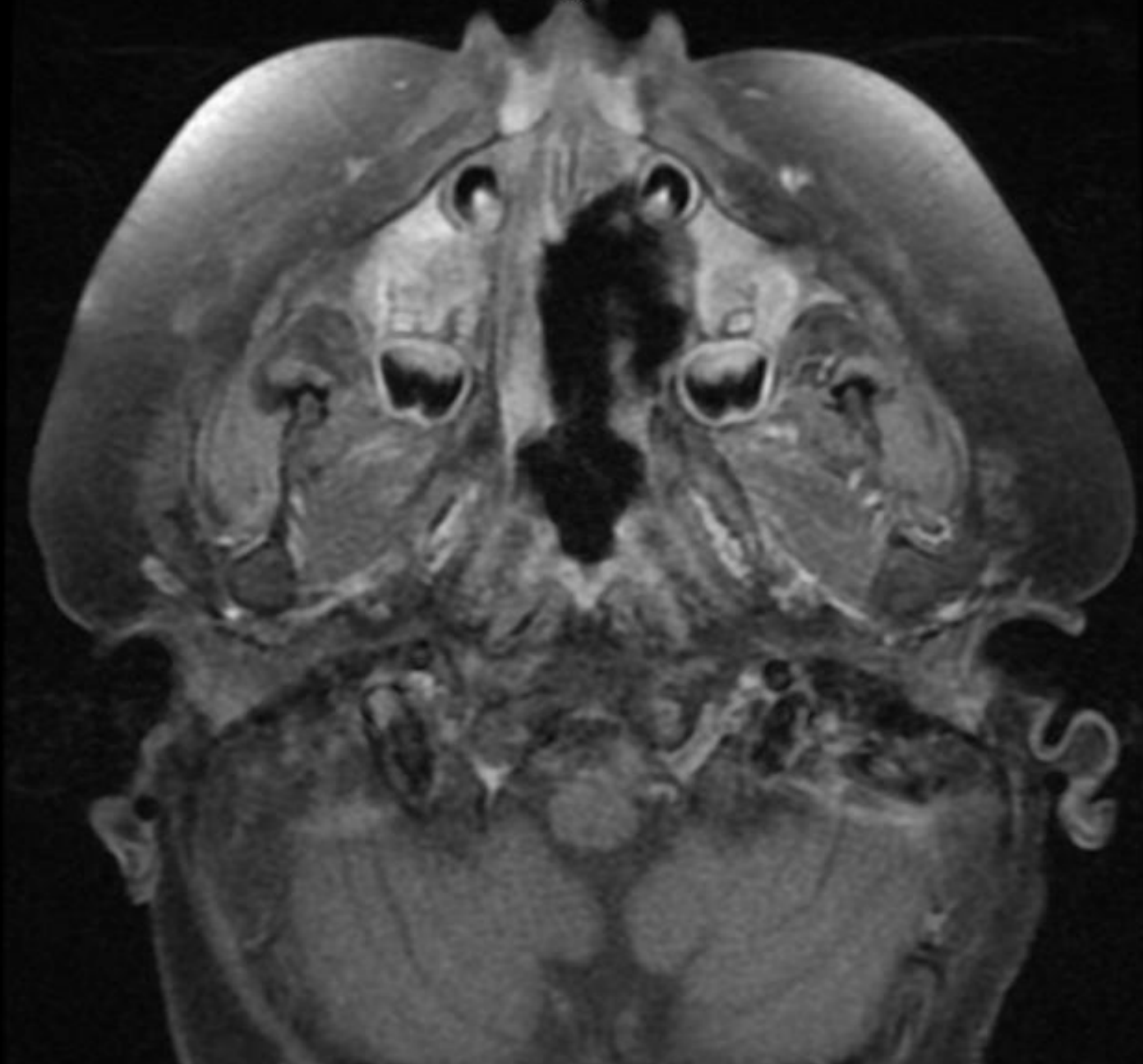
MR (T2 FAT SAT), 2/11/2012

[H]

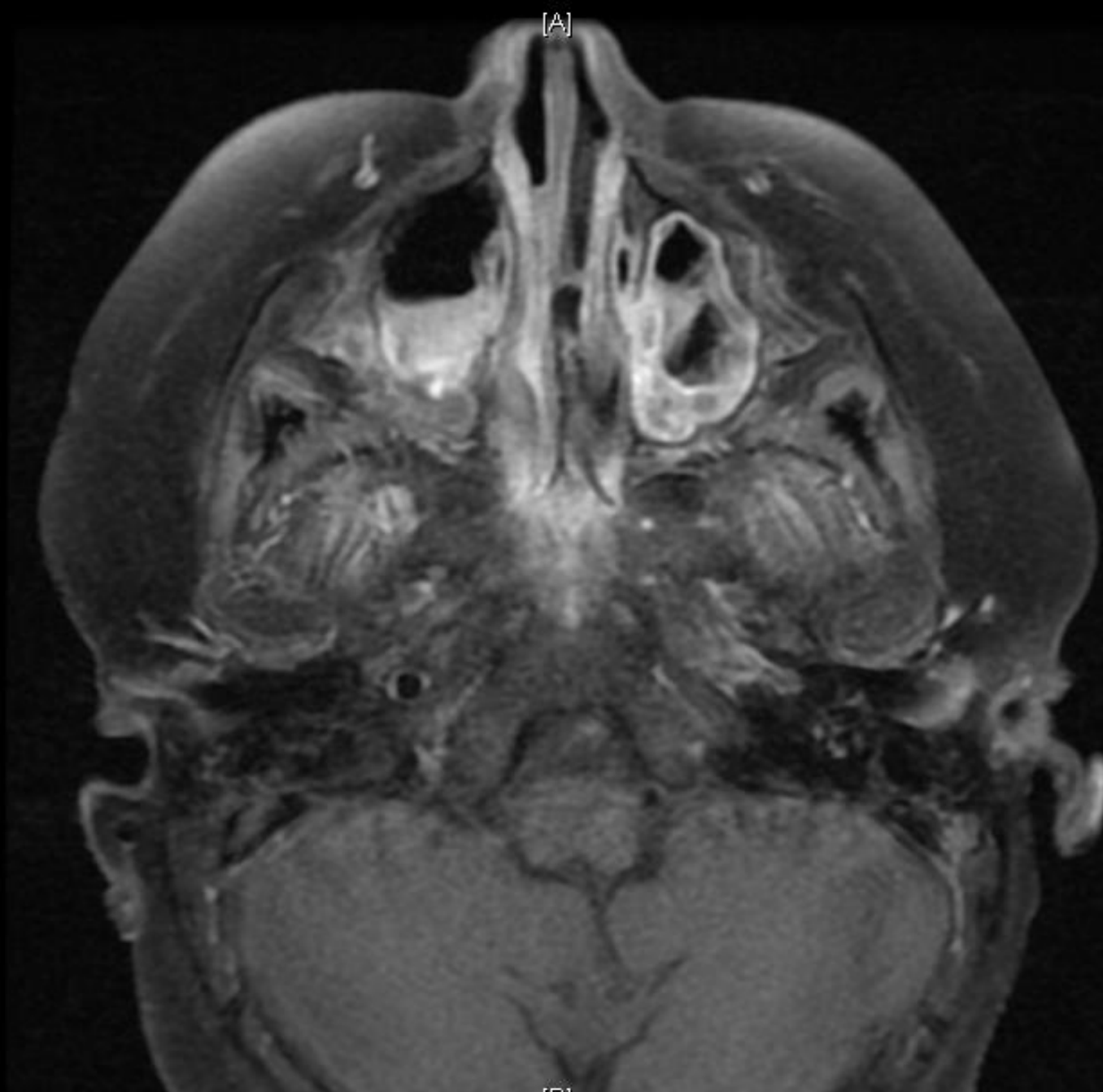


MR (T1 FS post contrast), 2/15/2012

[A]



MR (T1 FS post contrast), 2/15/2012



MR (T1 FS post contrast), 2/15/2012

