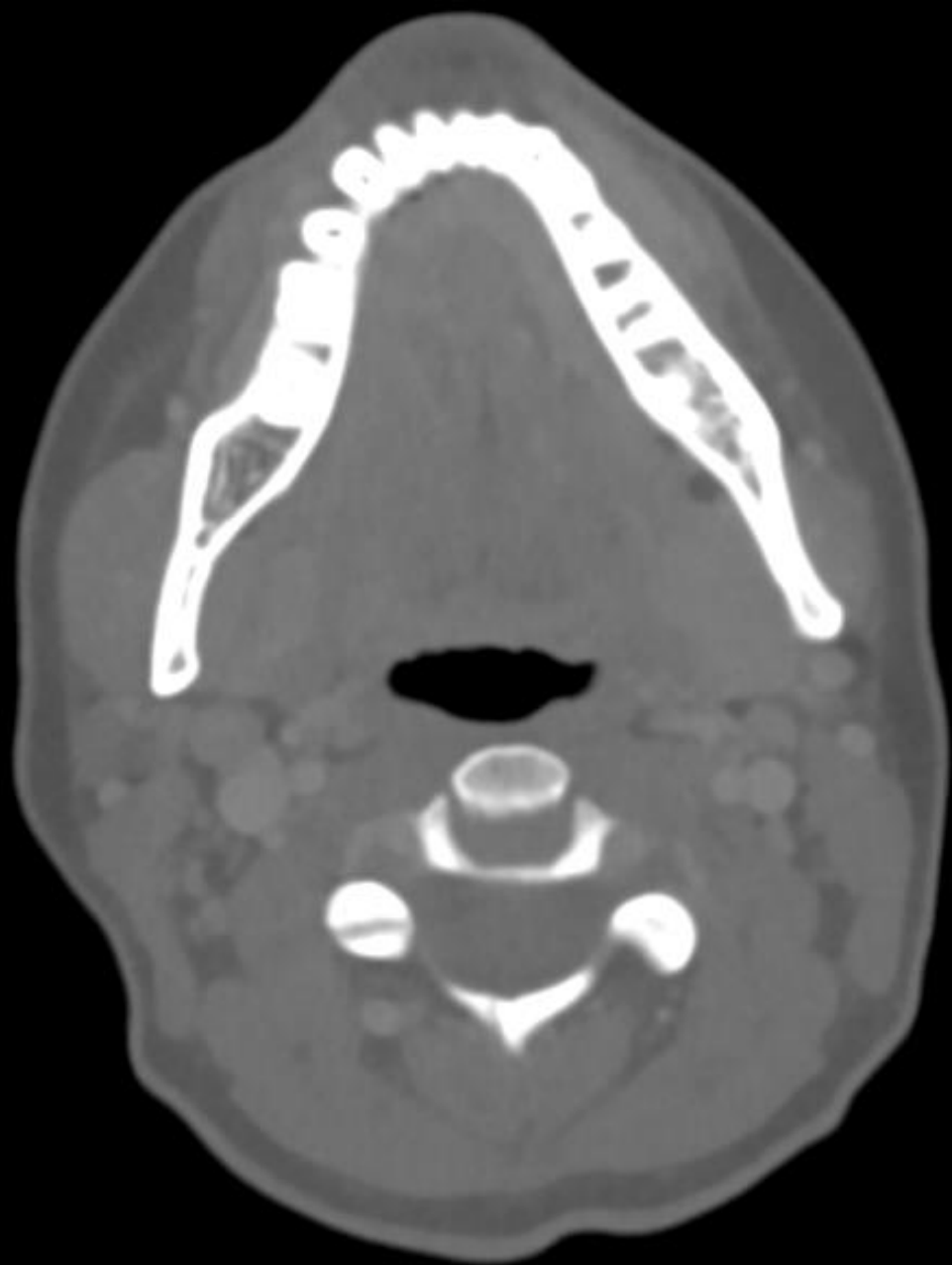
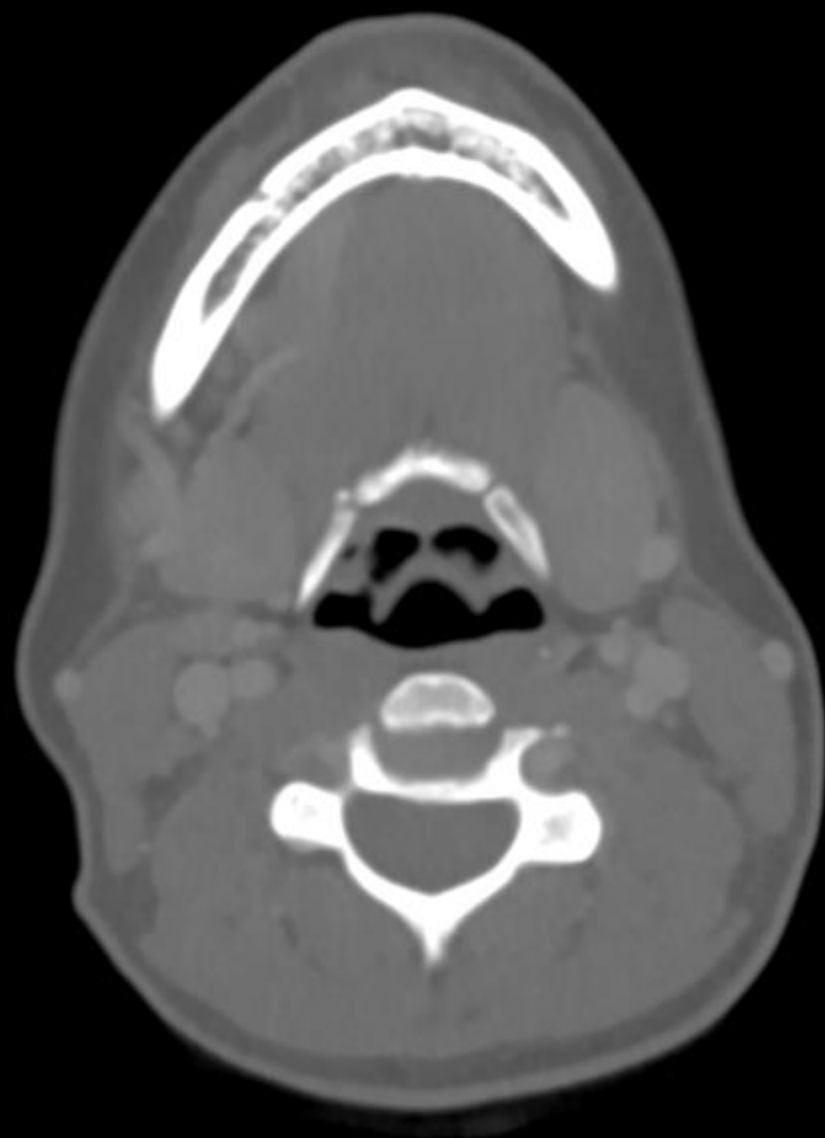
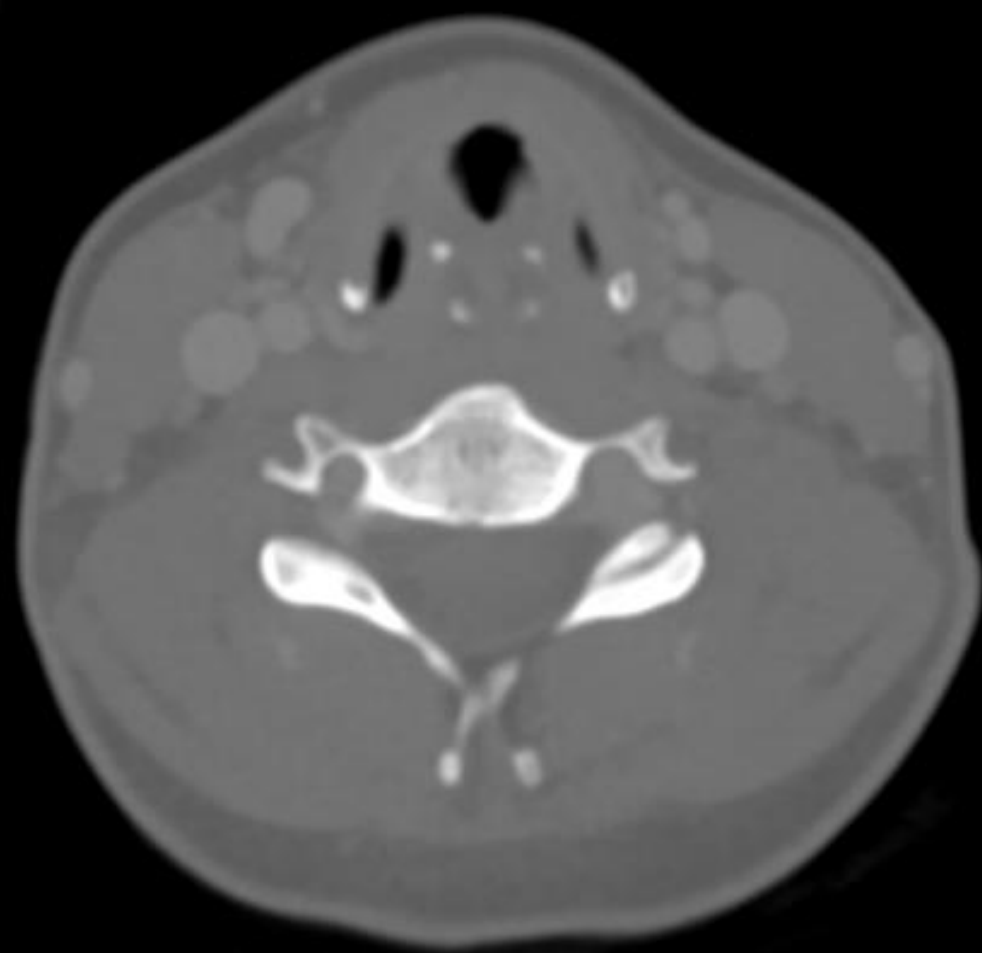
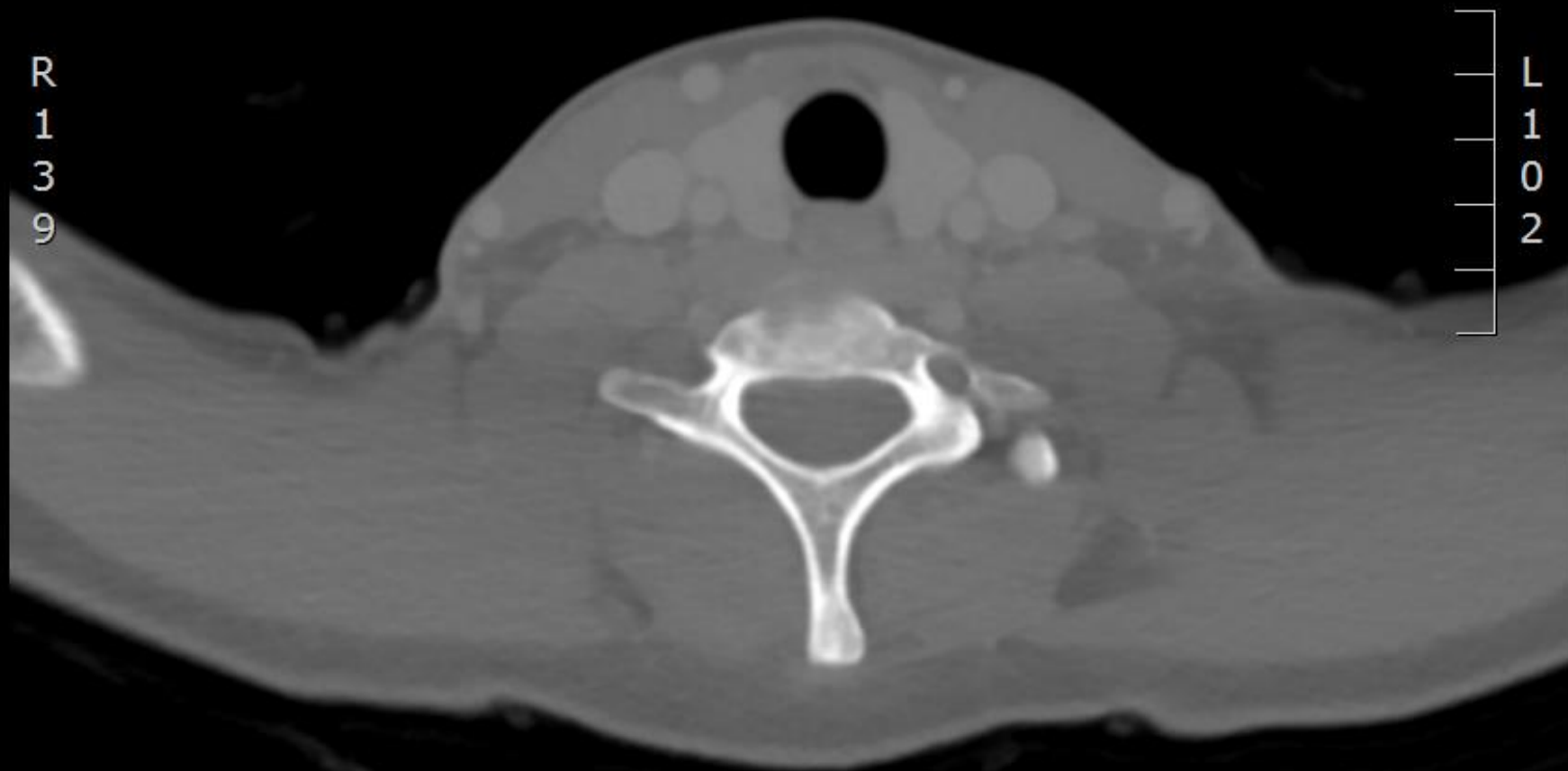
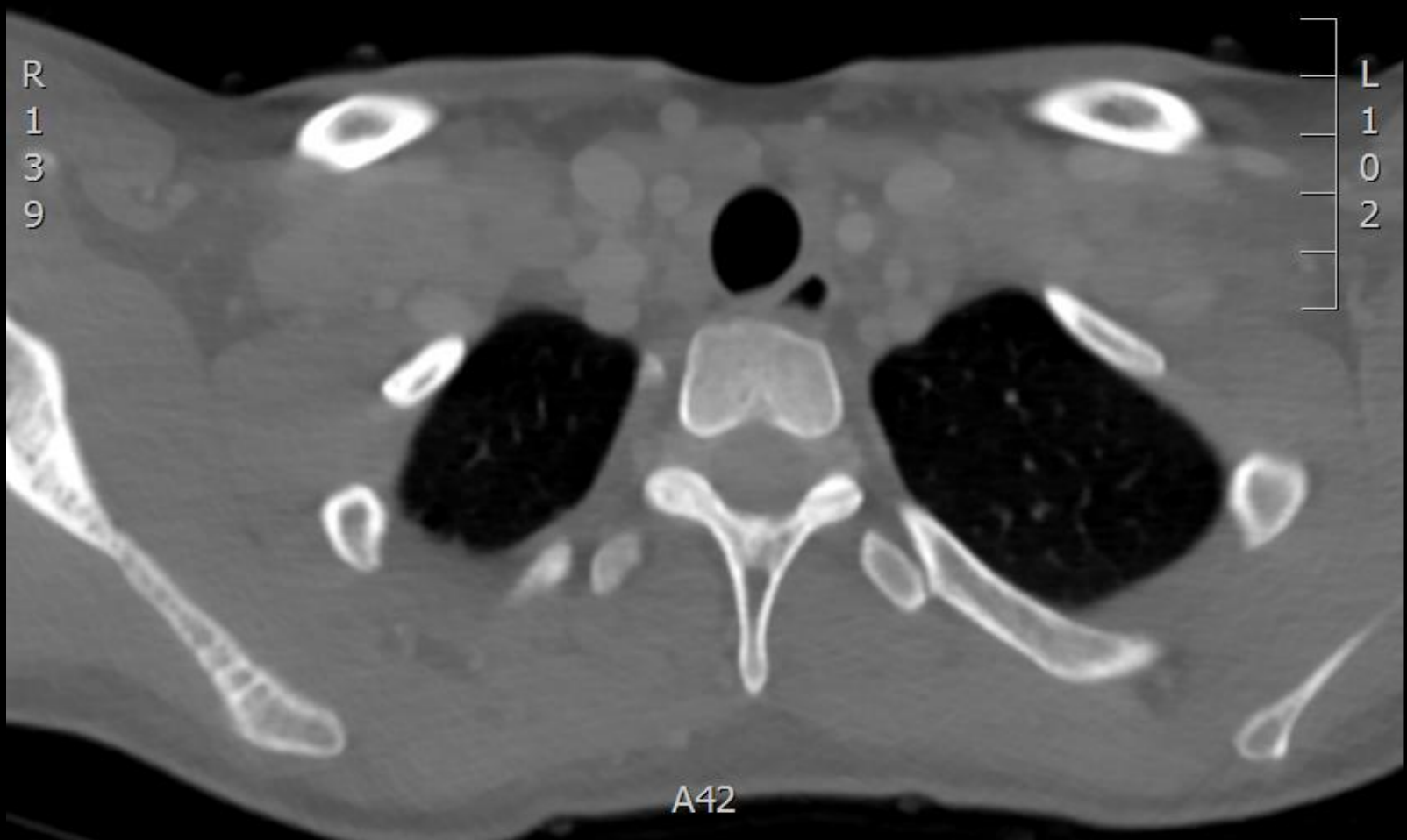
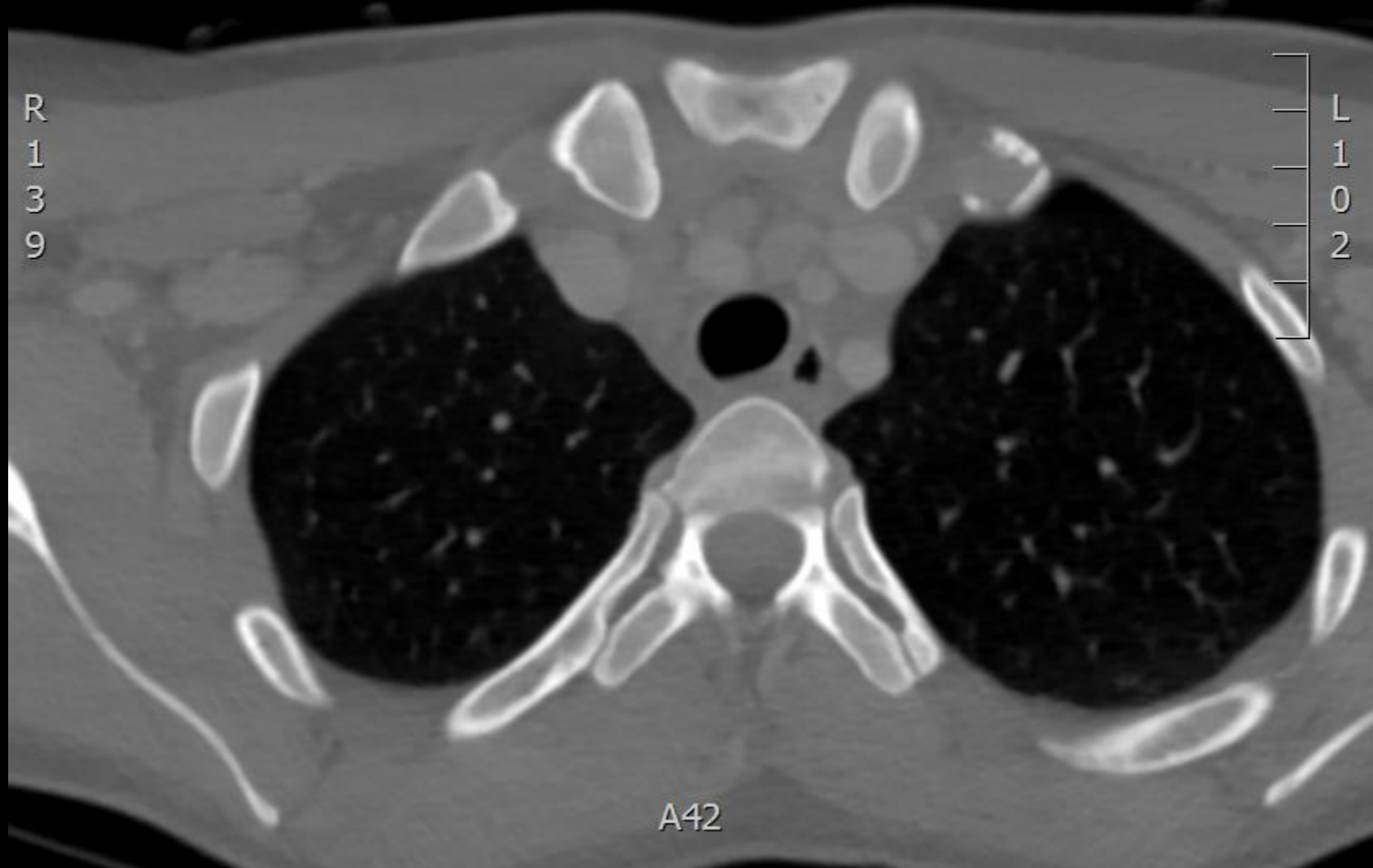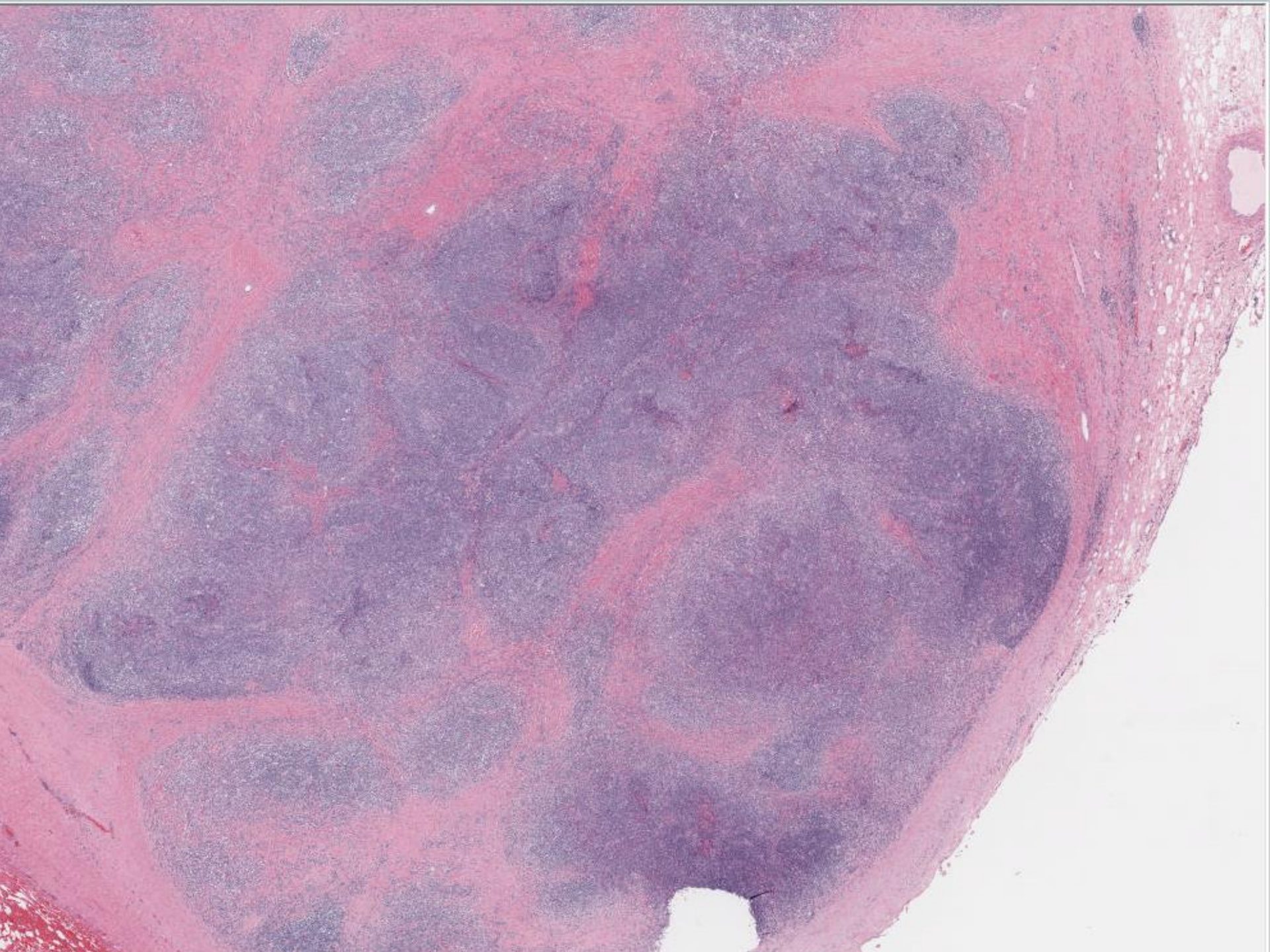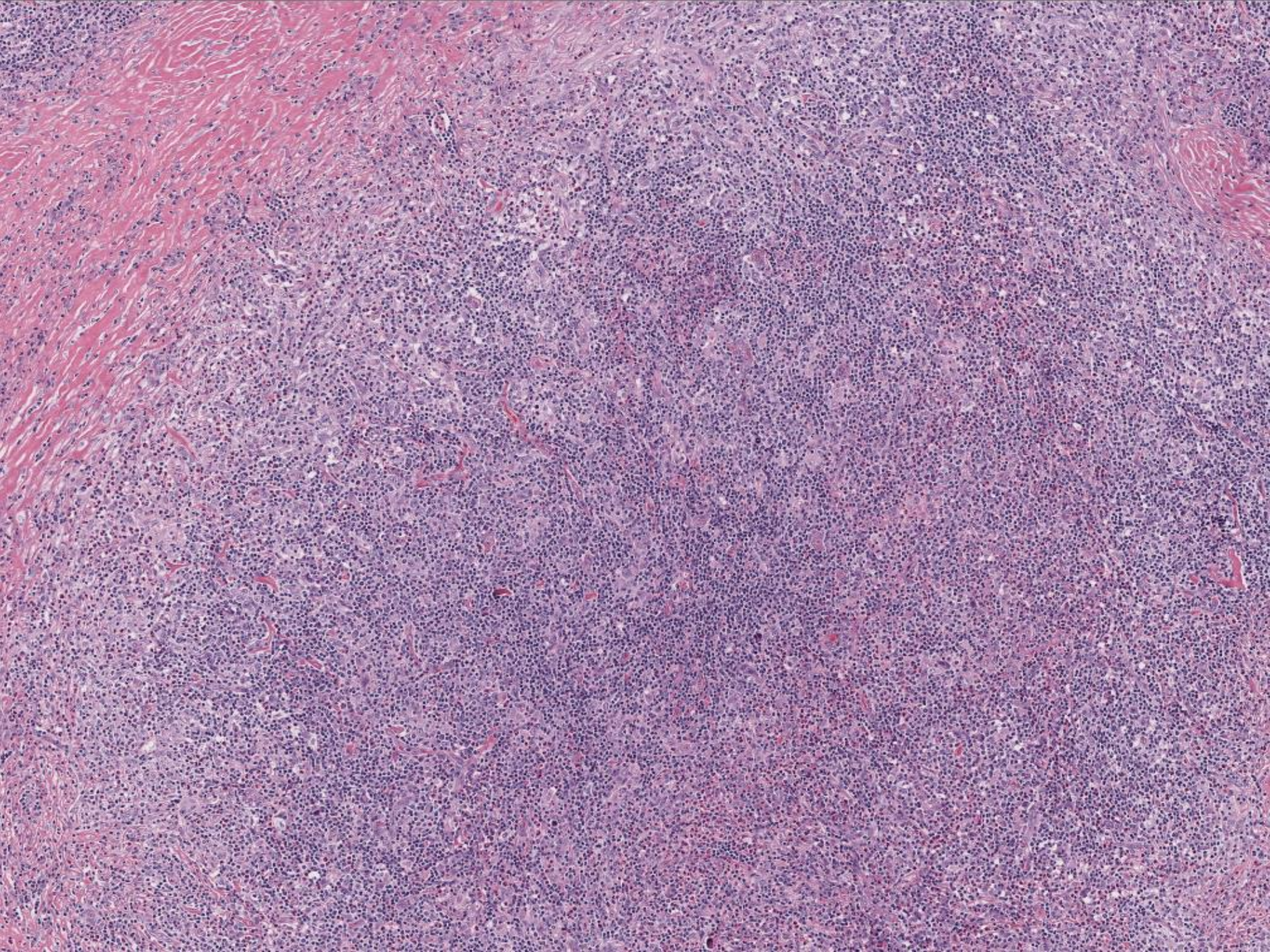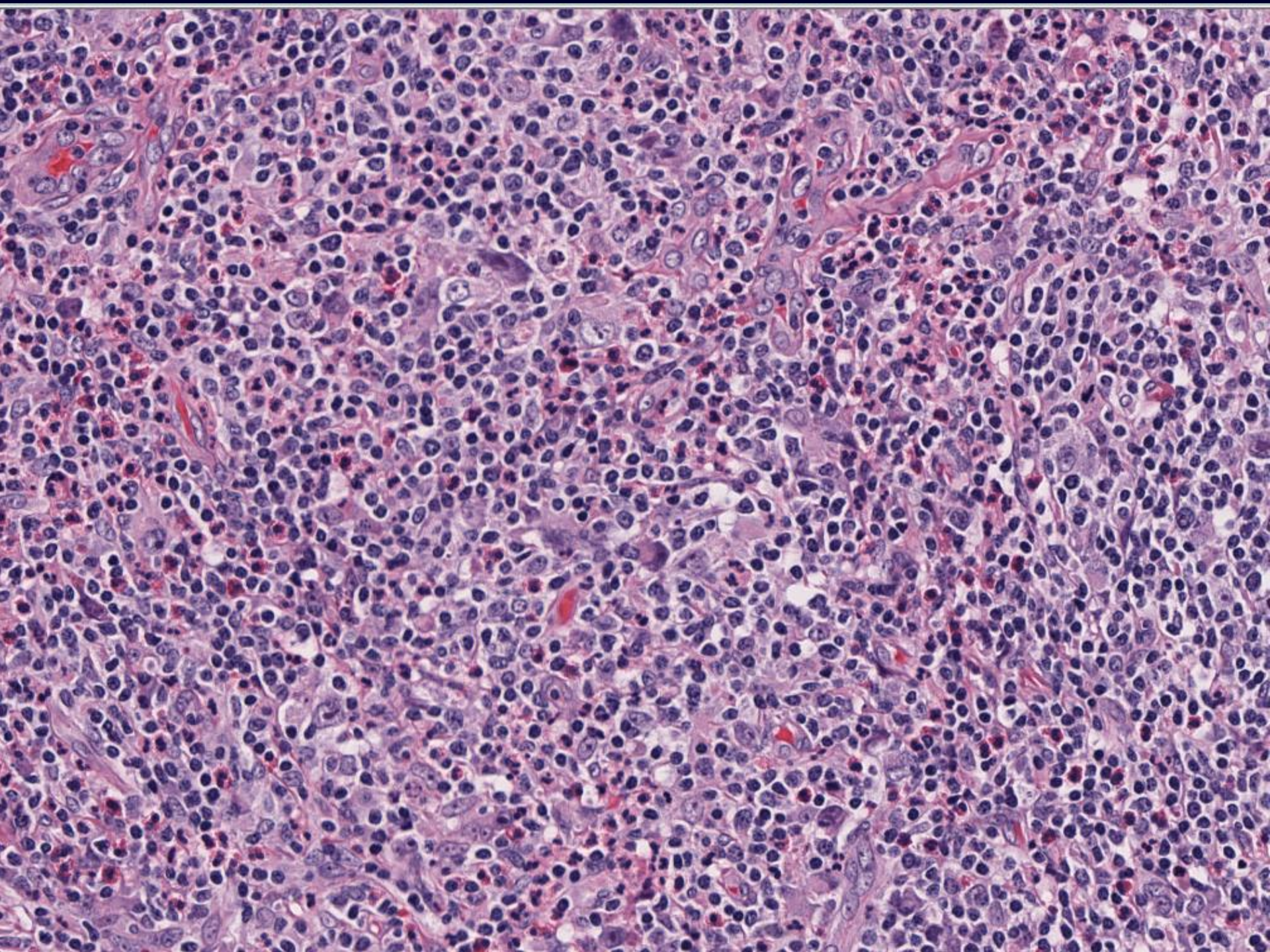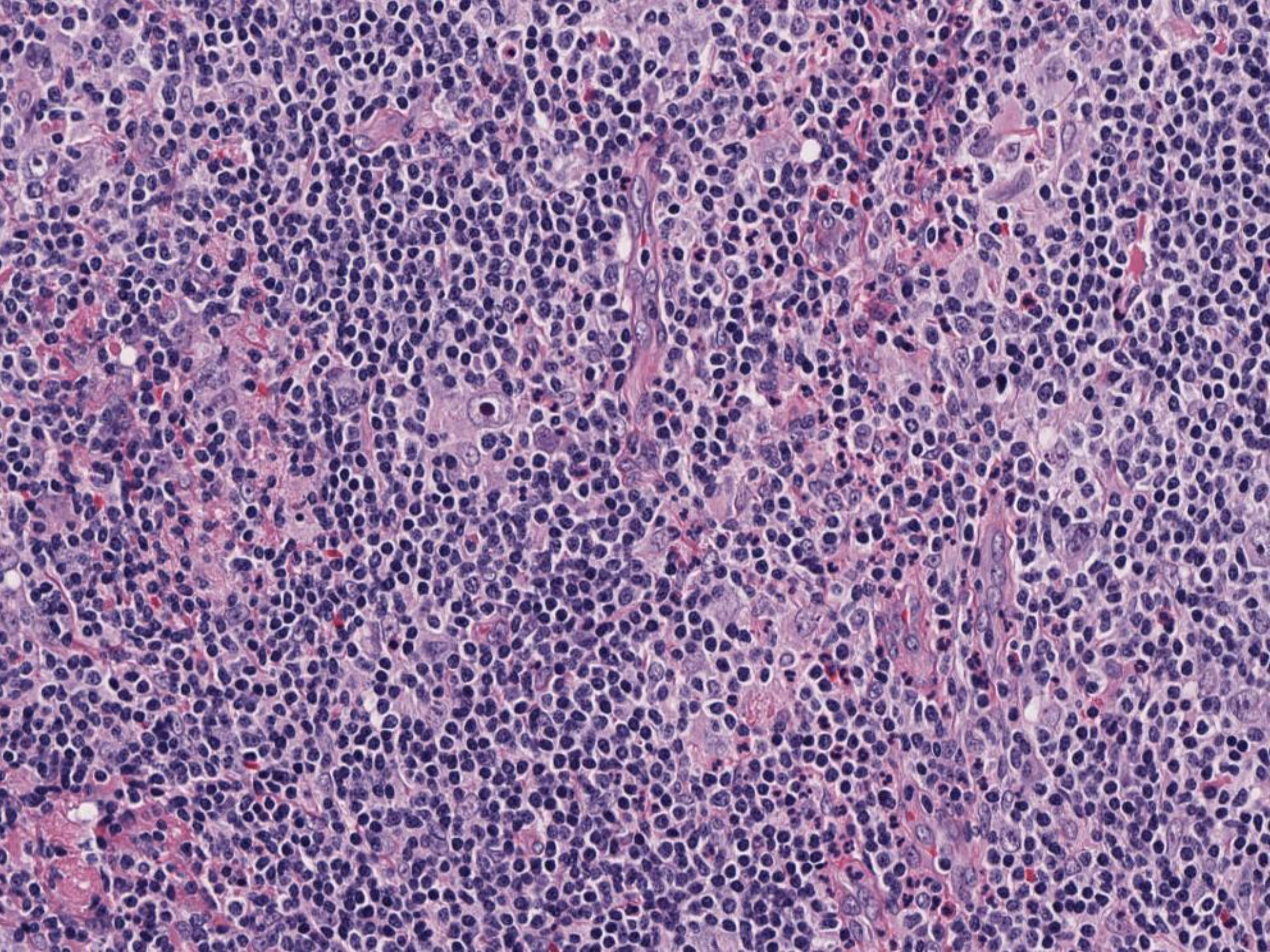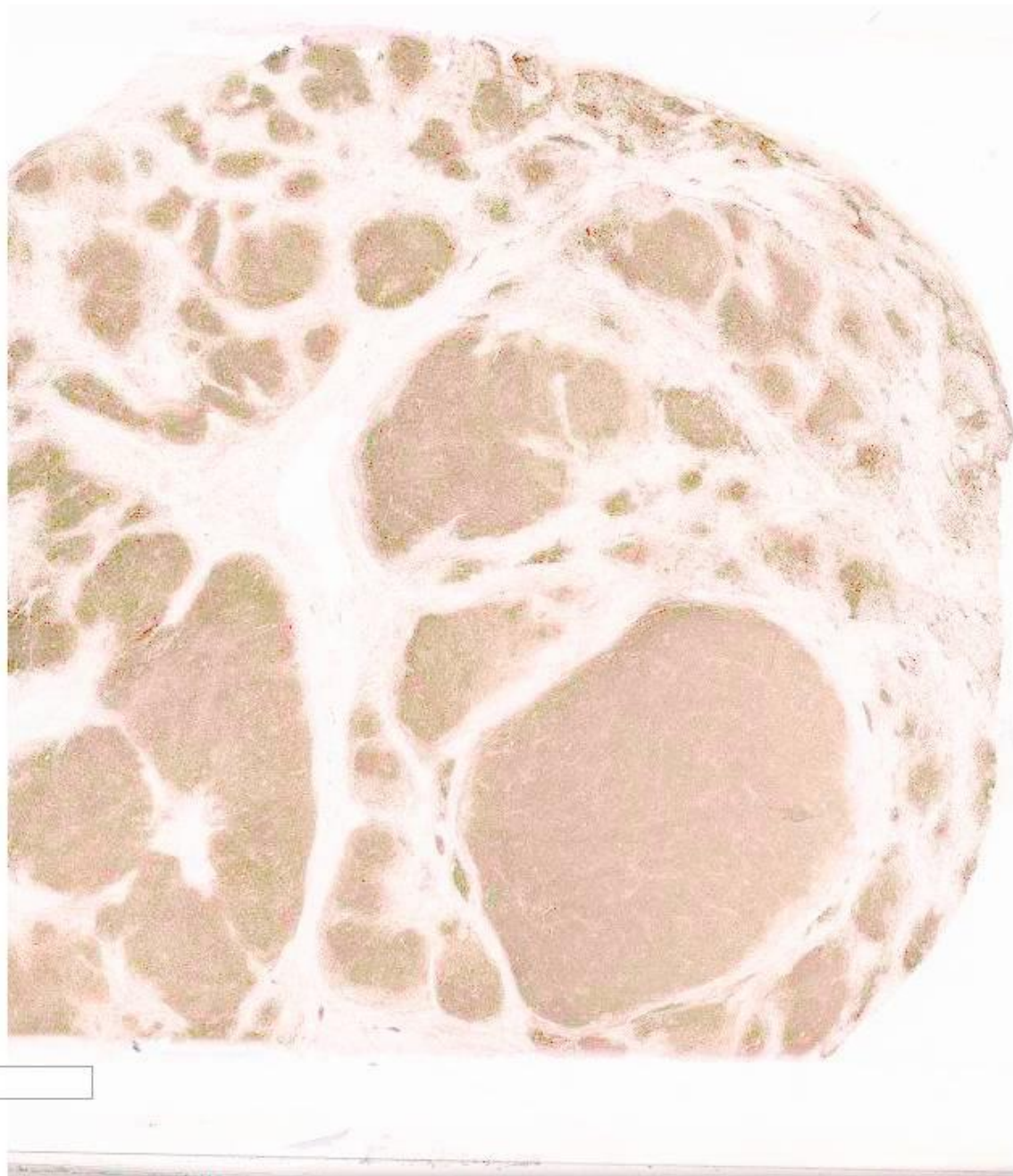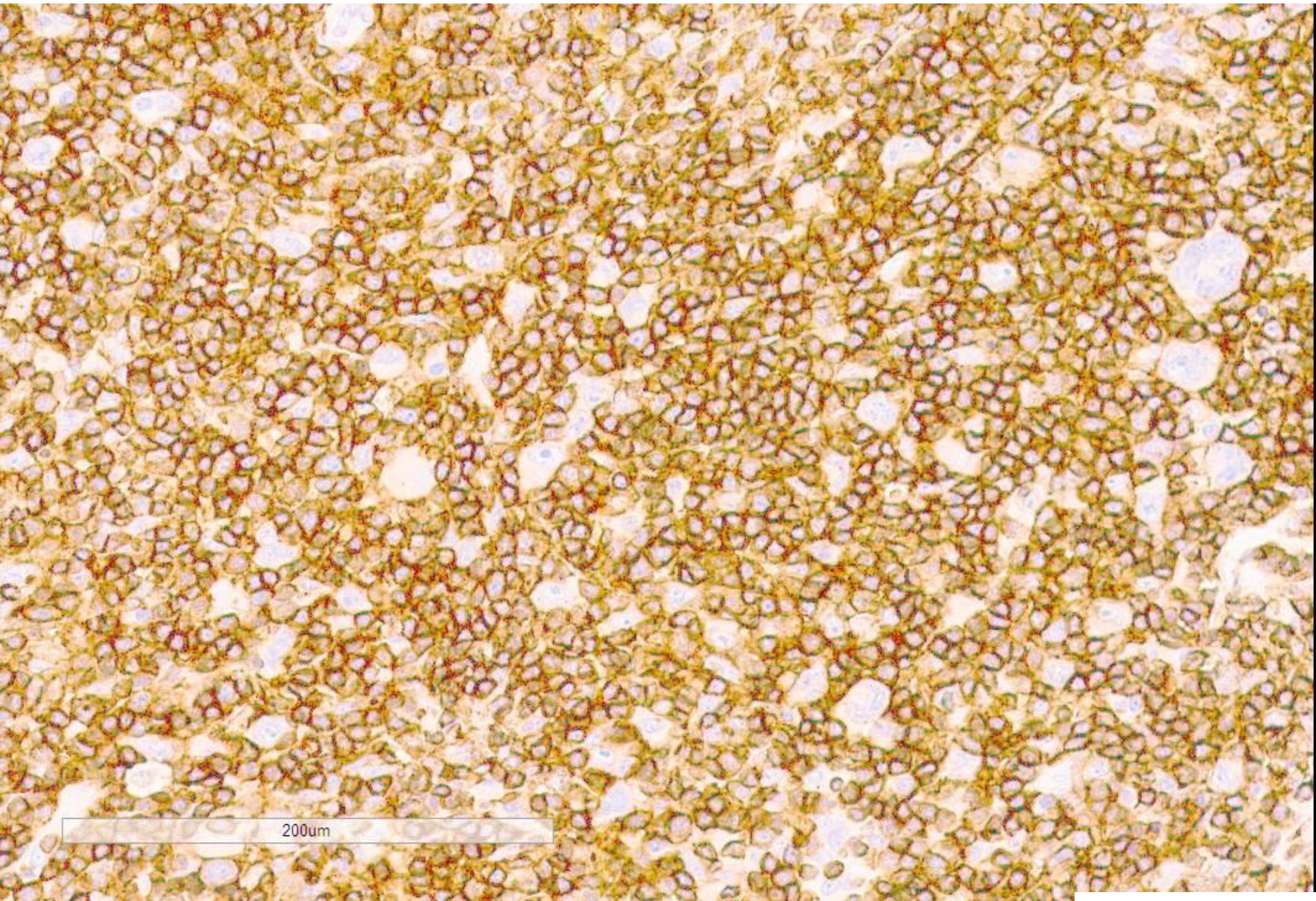
7mm

CD45

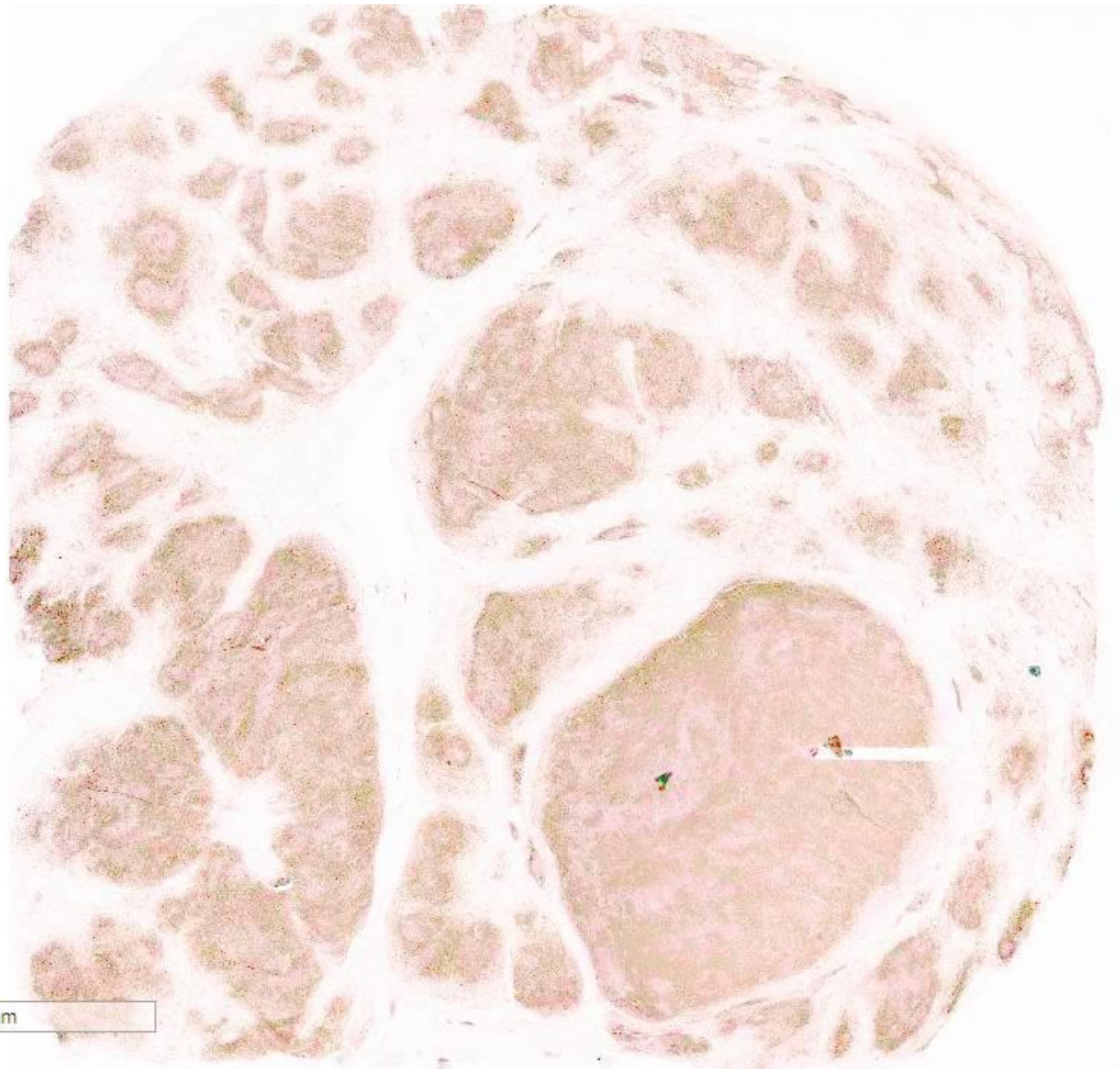


600µm

CD45

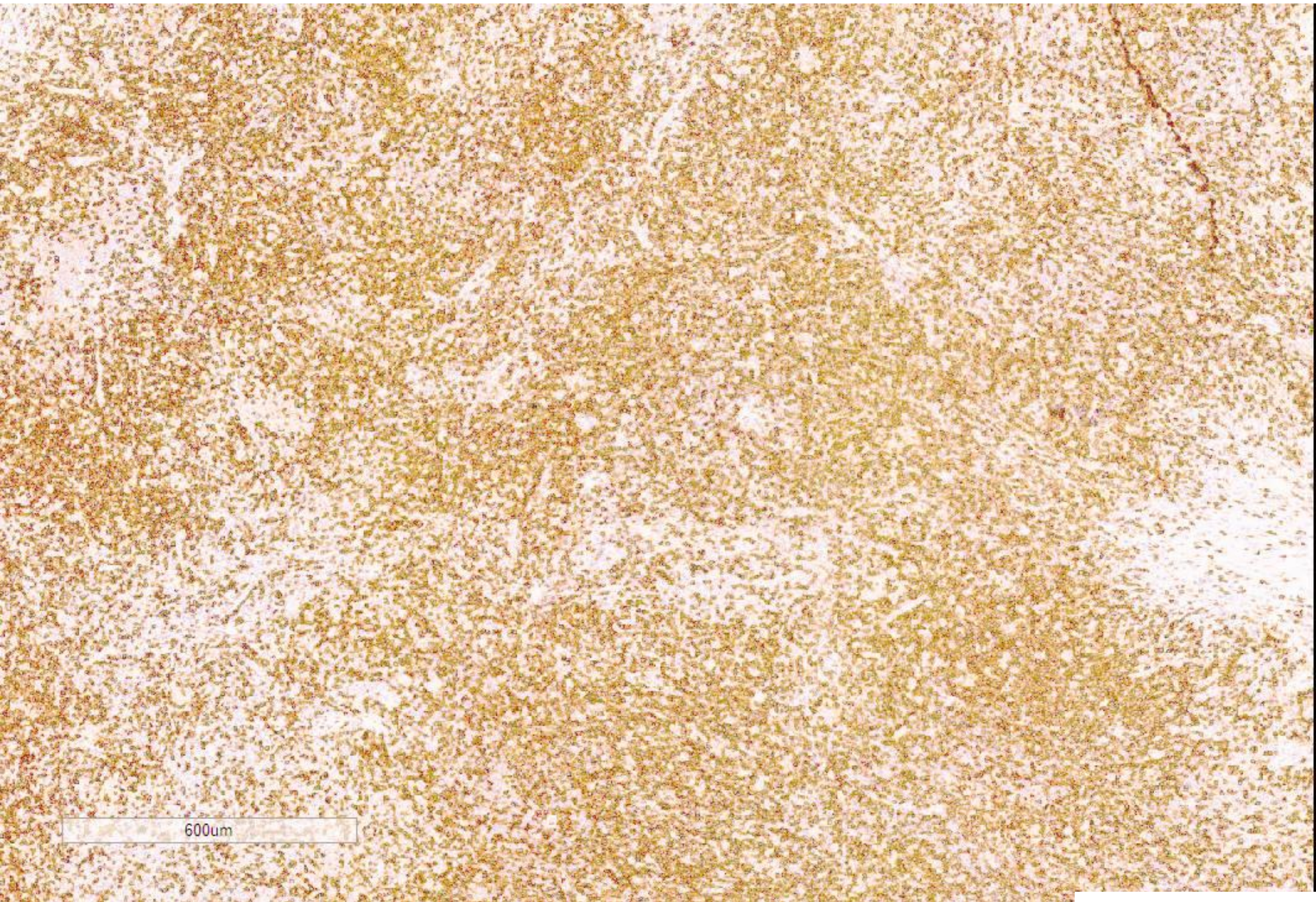


CD45

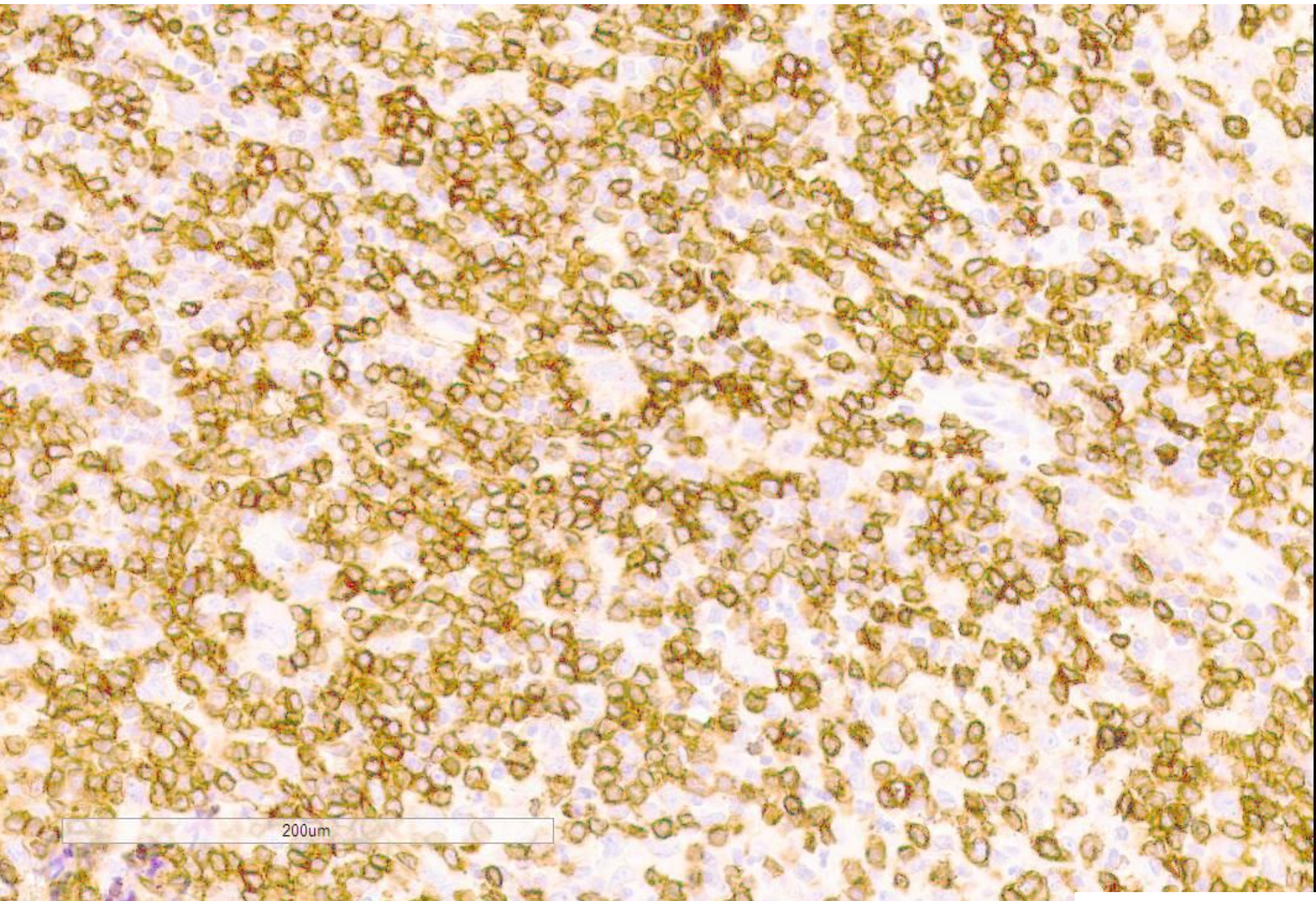


6mm

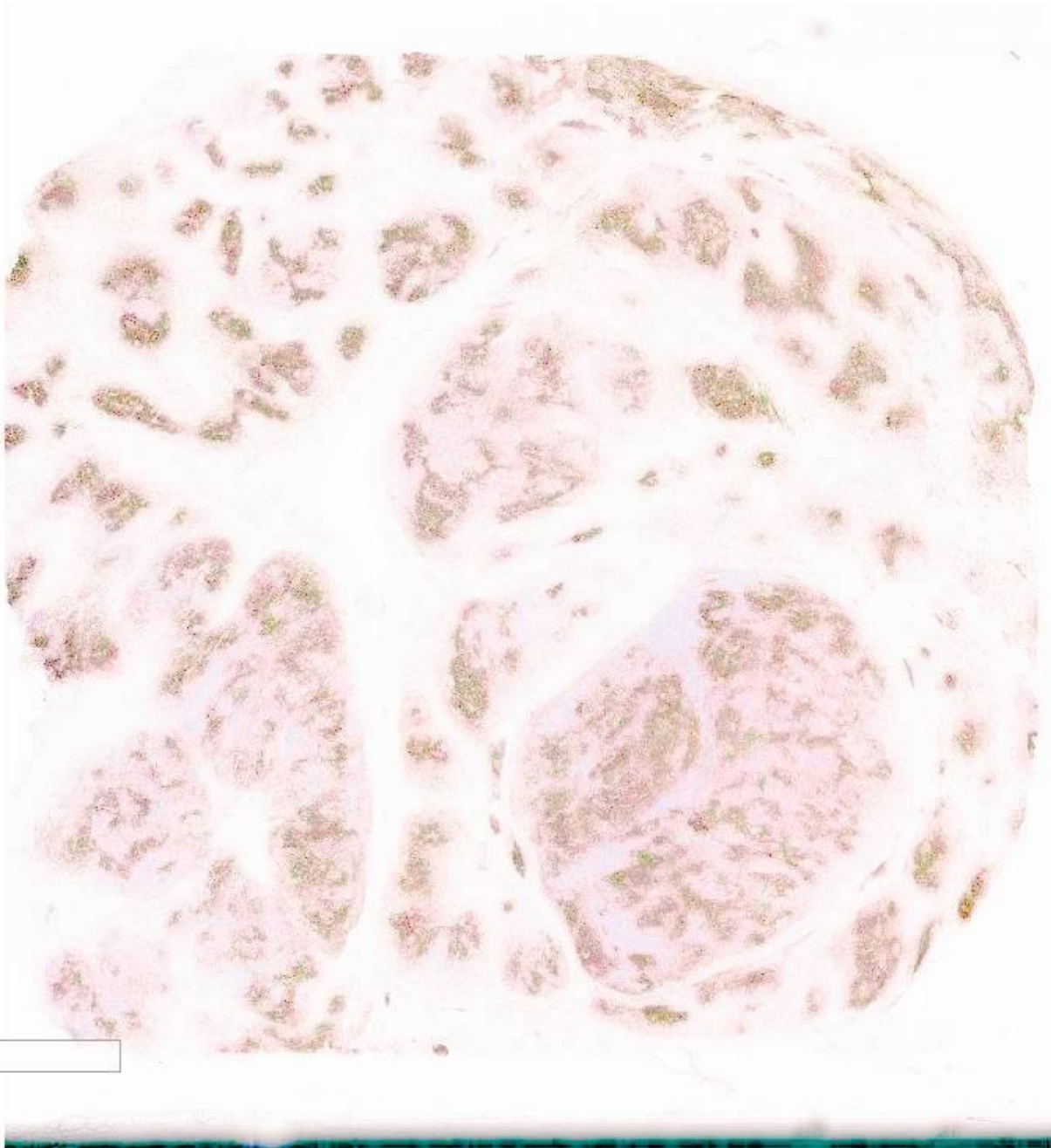
CD3



CD3

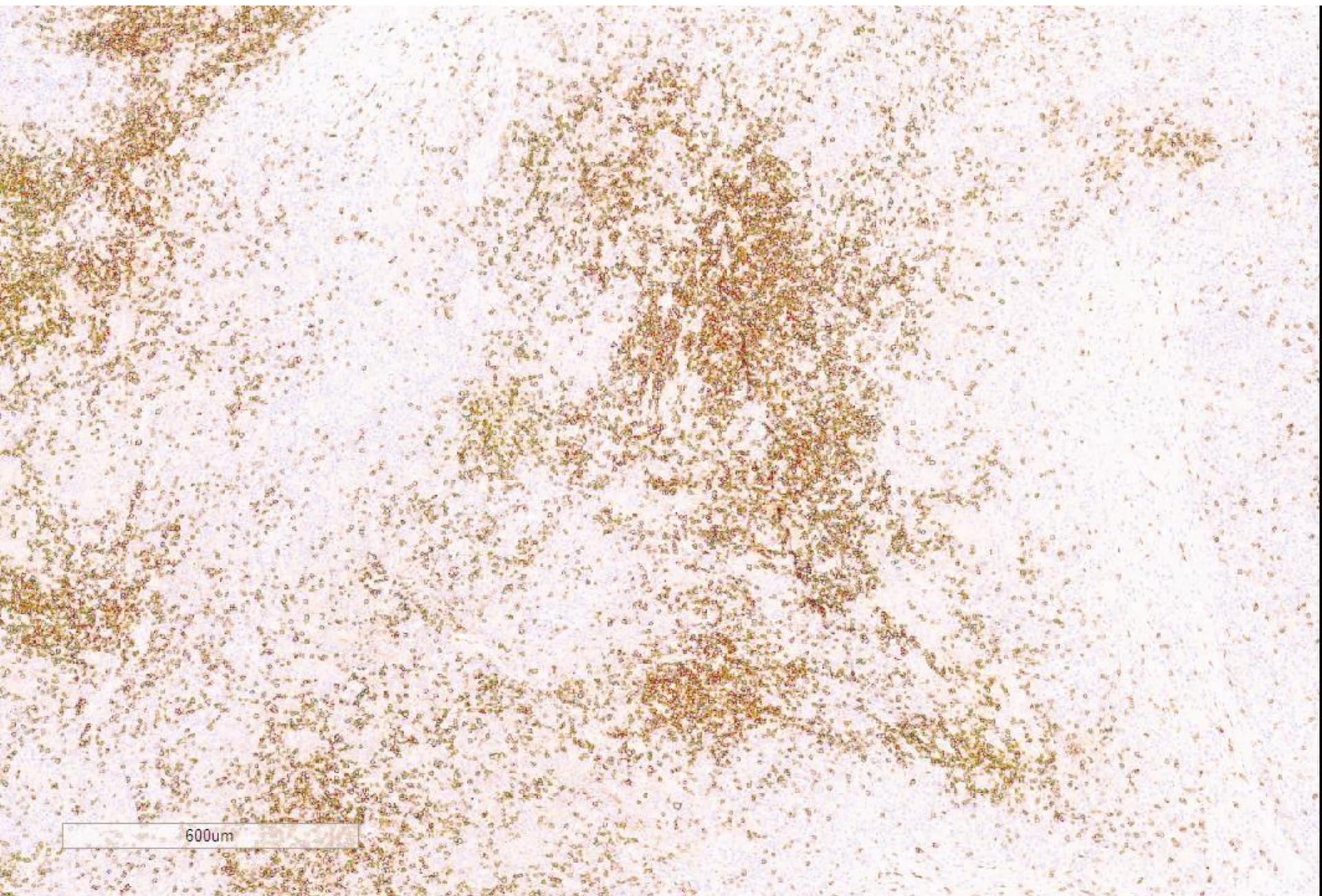


CD3



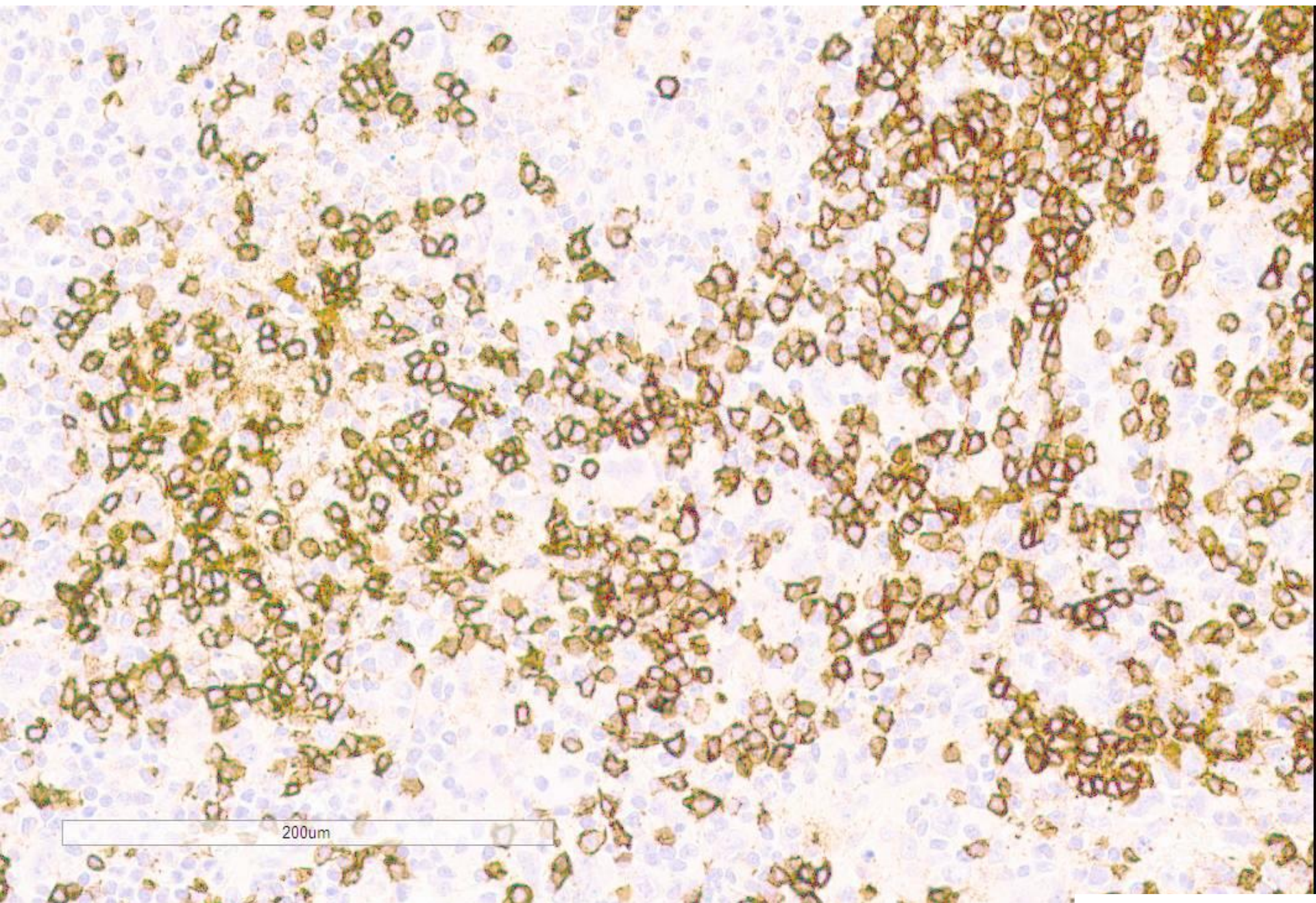
7mm

CD20

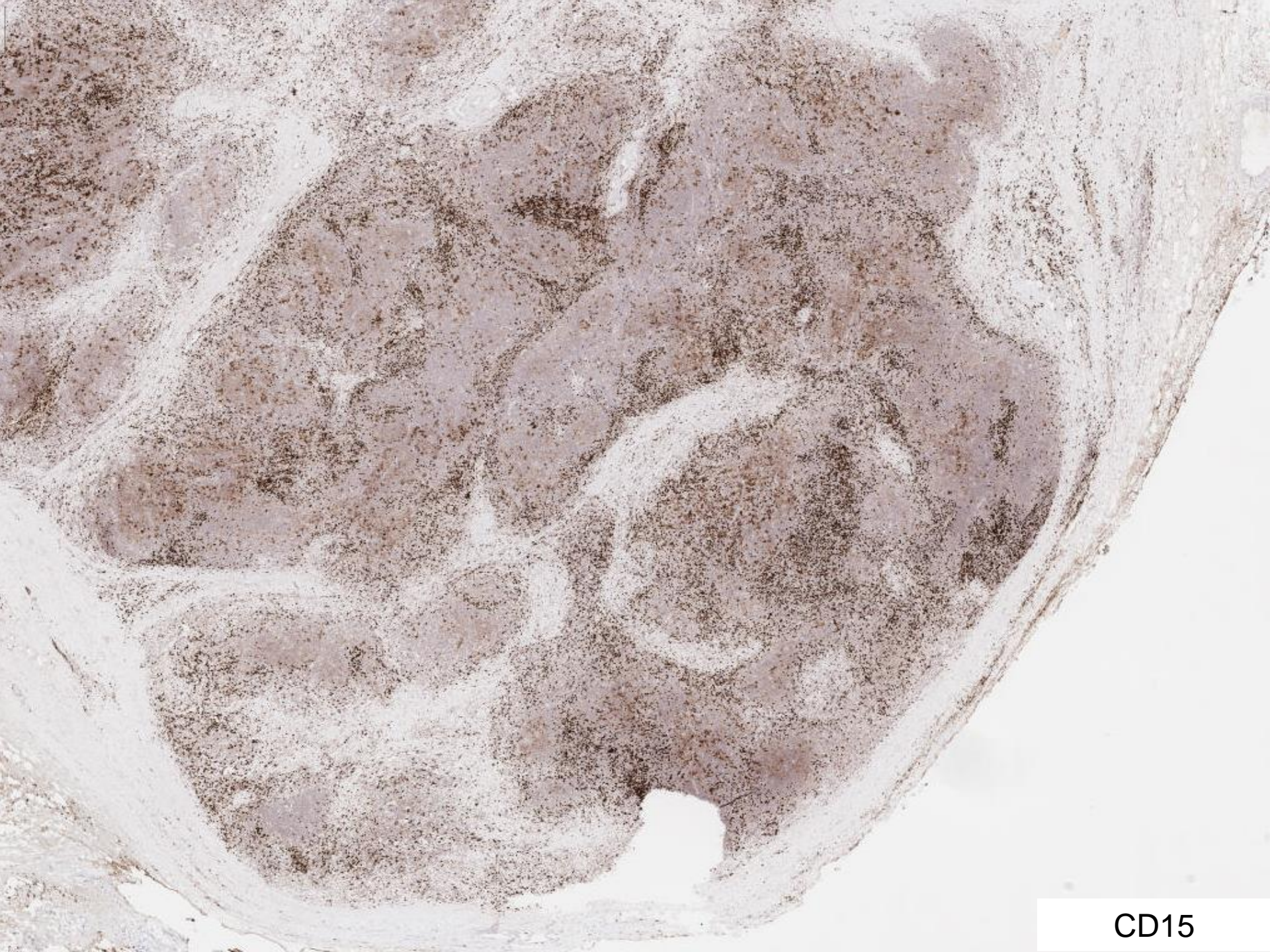


600um

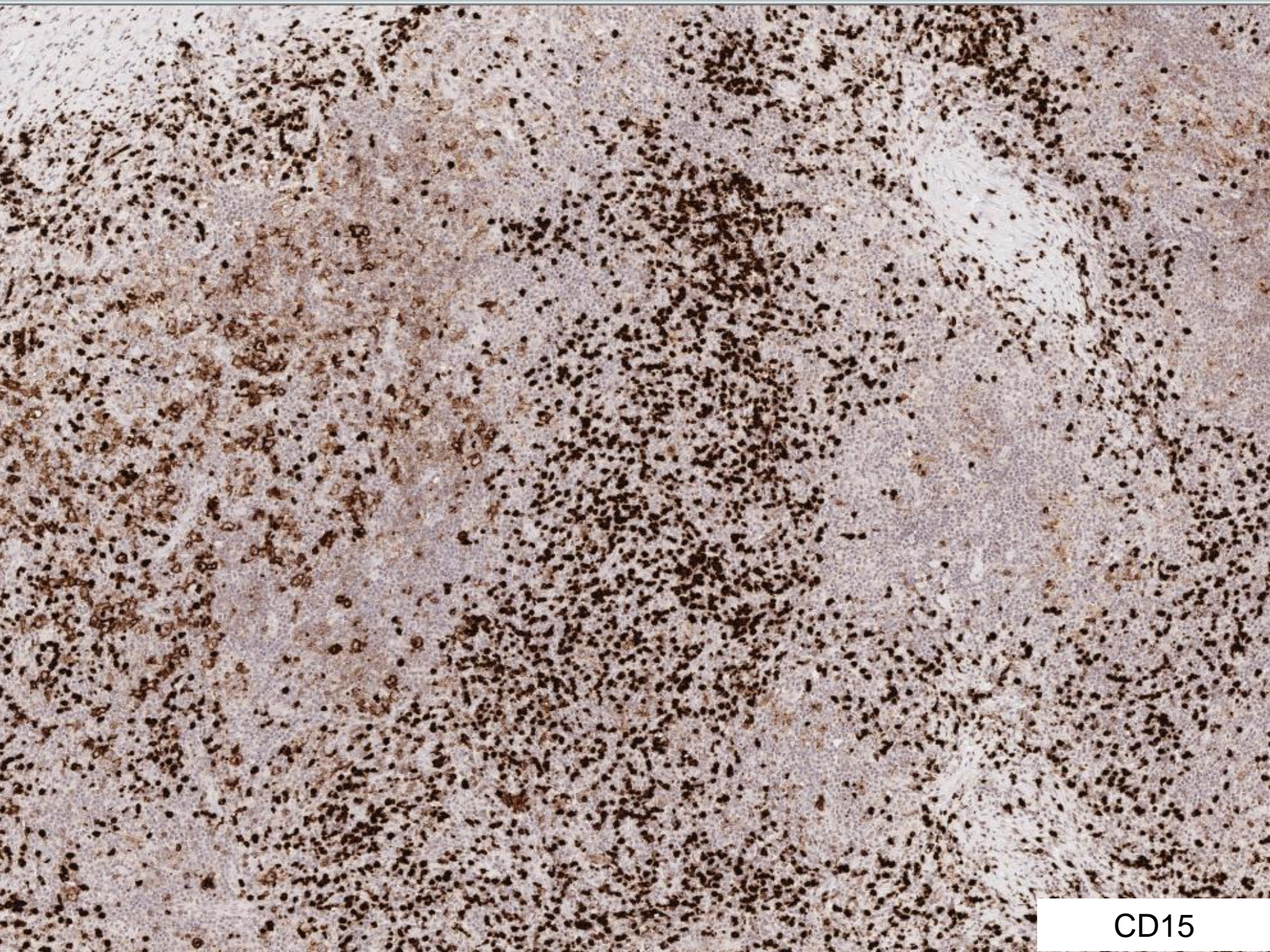
CD20



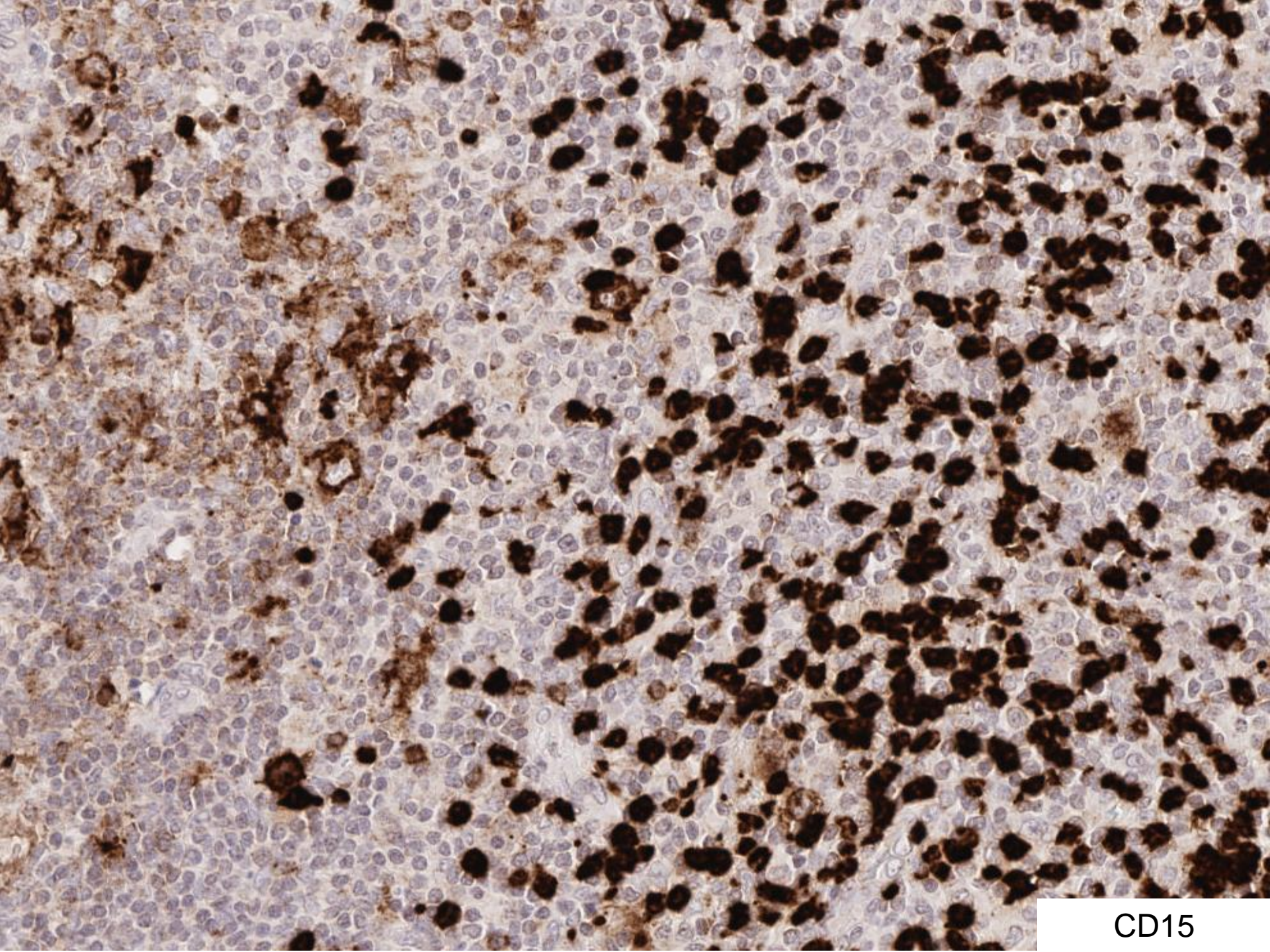
CD20



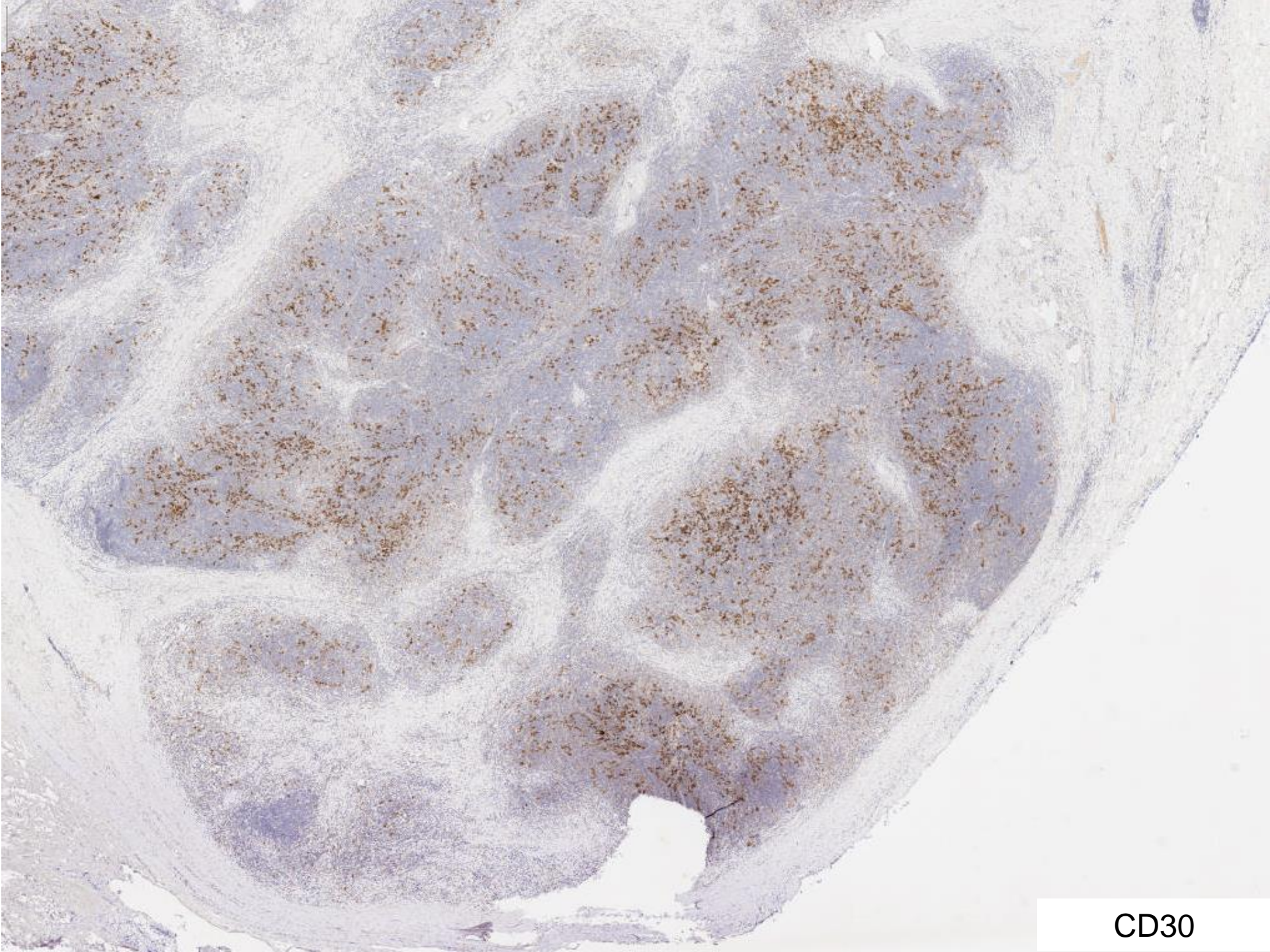
CD15



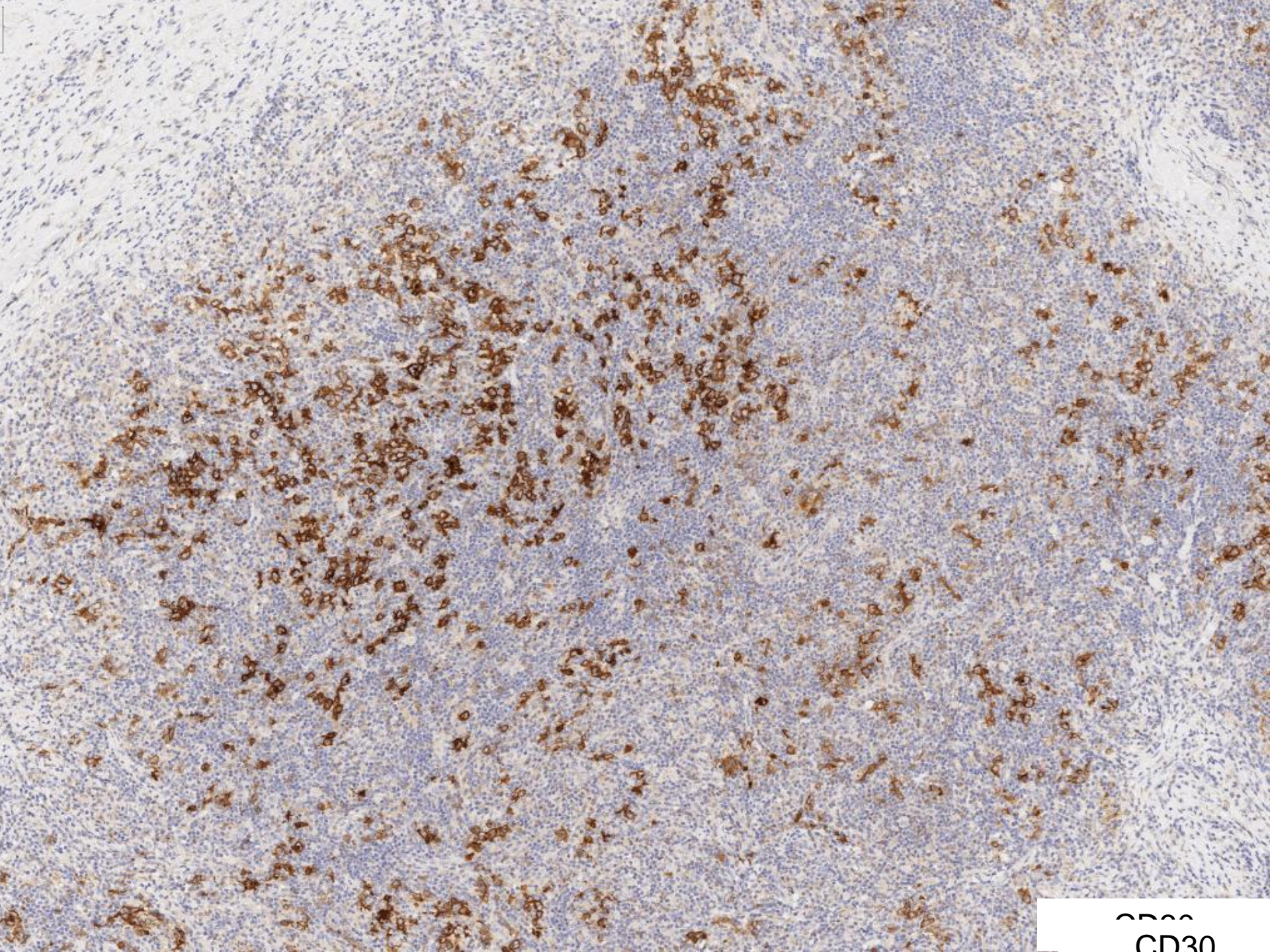
CD15



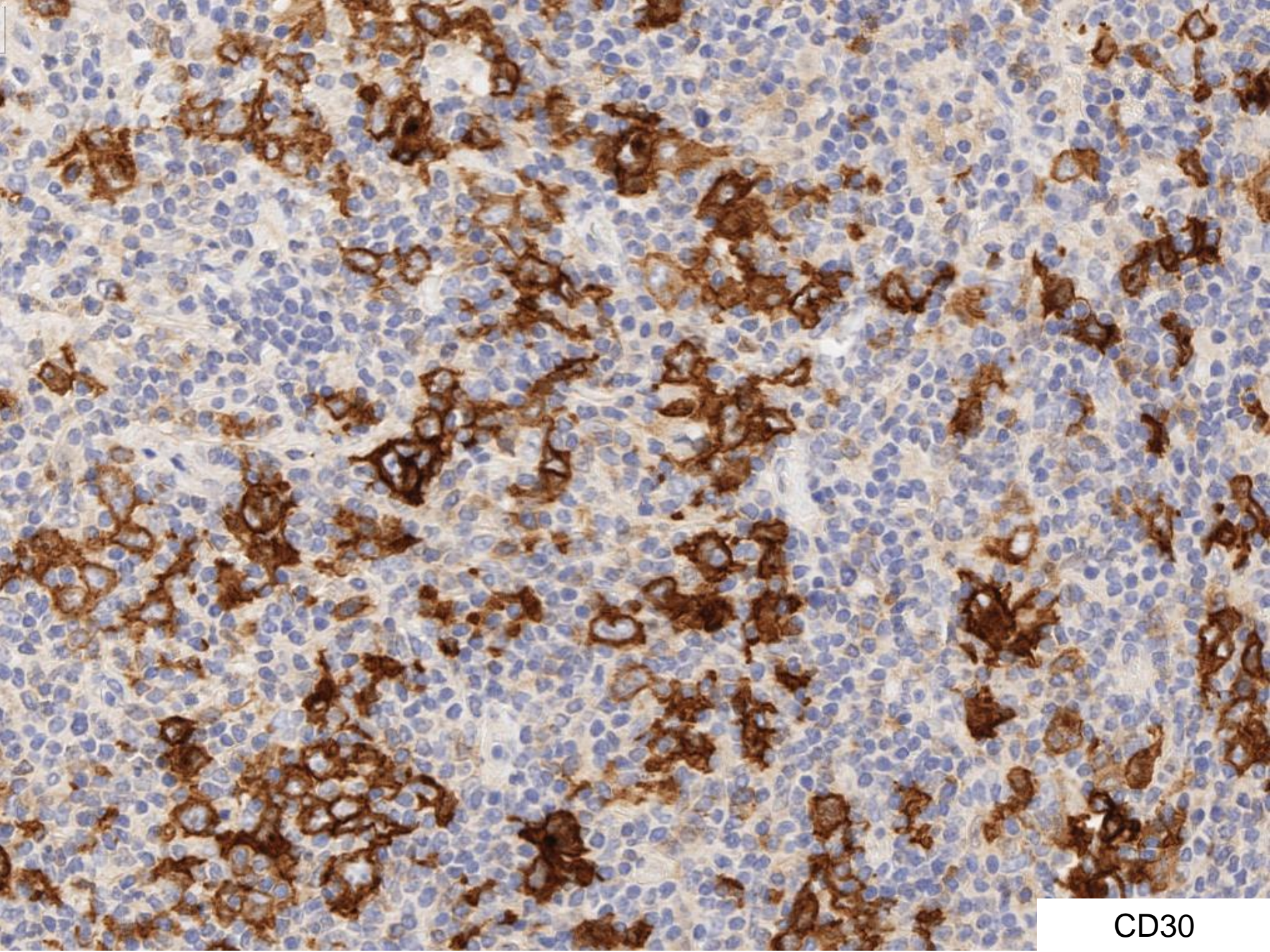
CD15



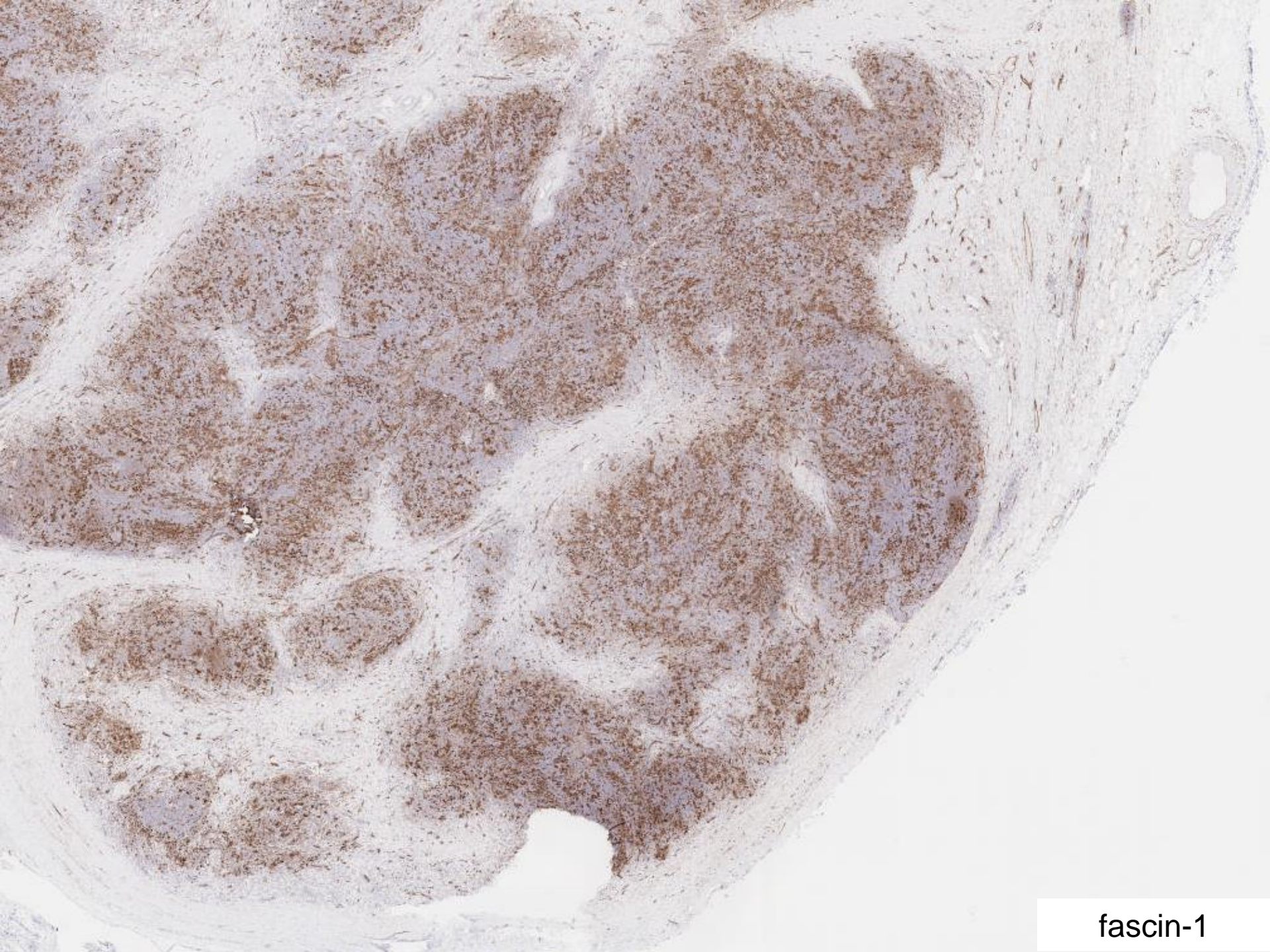
CD30



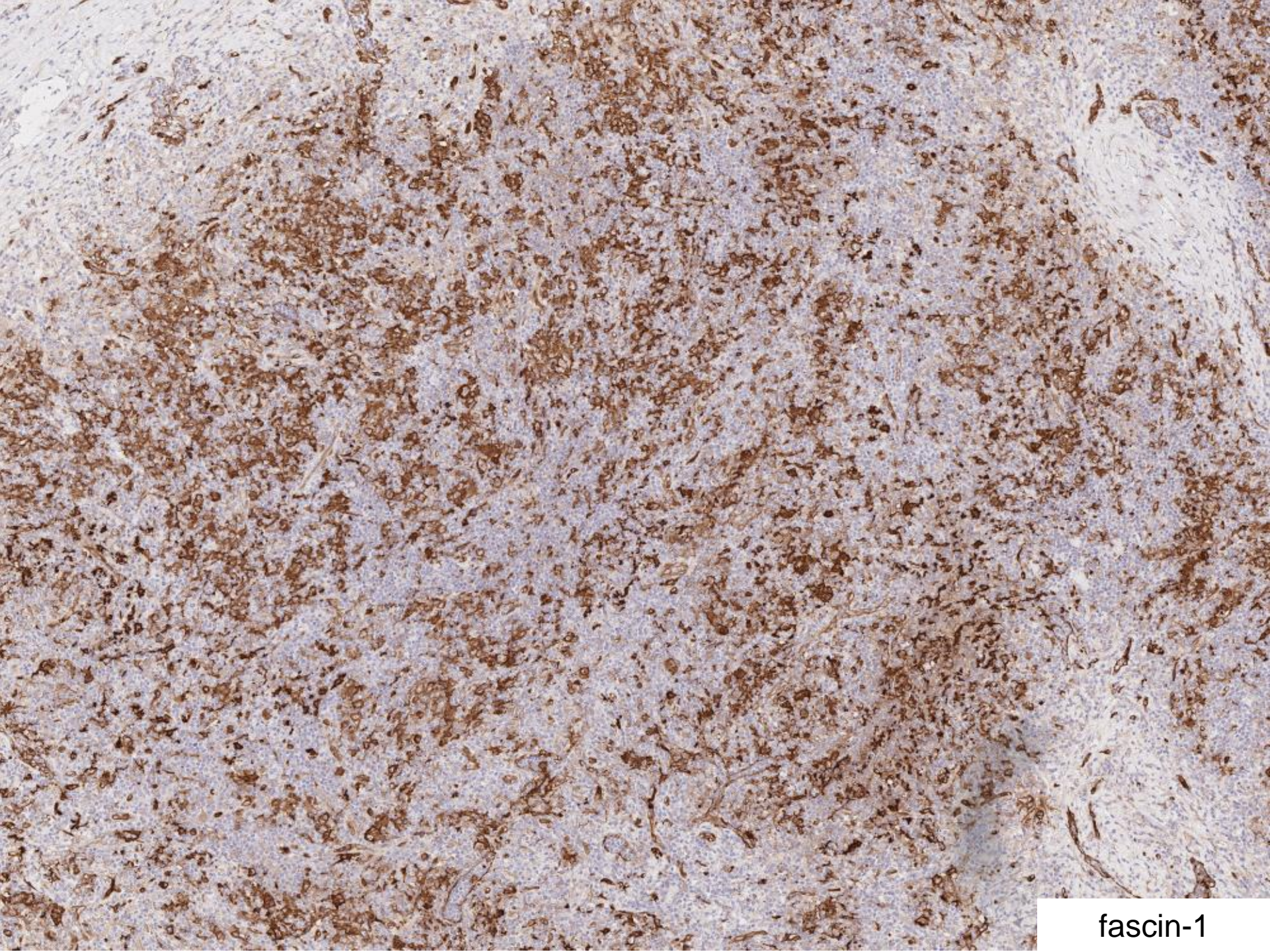
2533
CD30



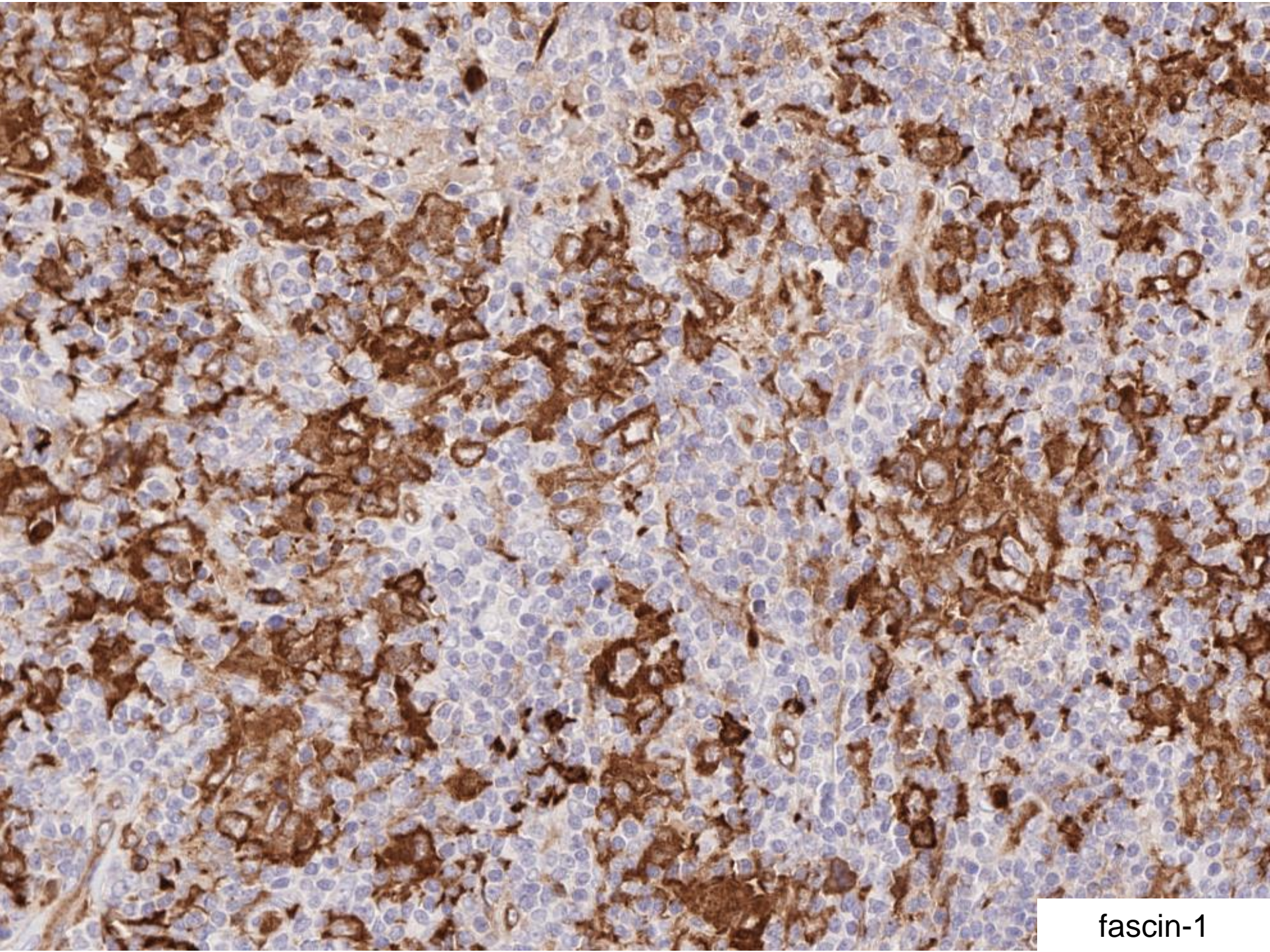
CD30



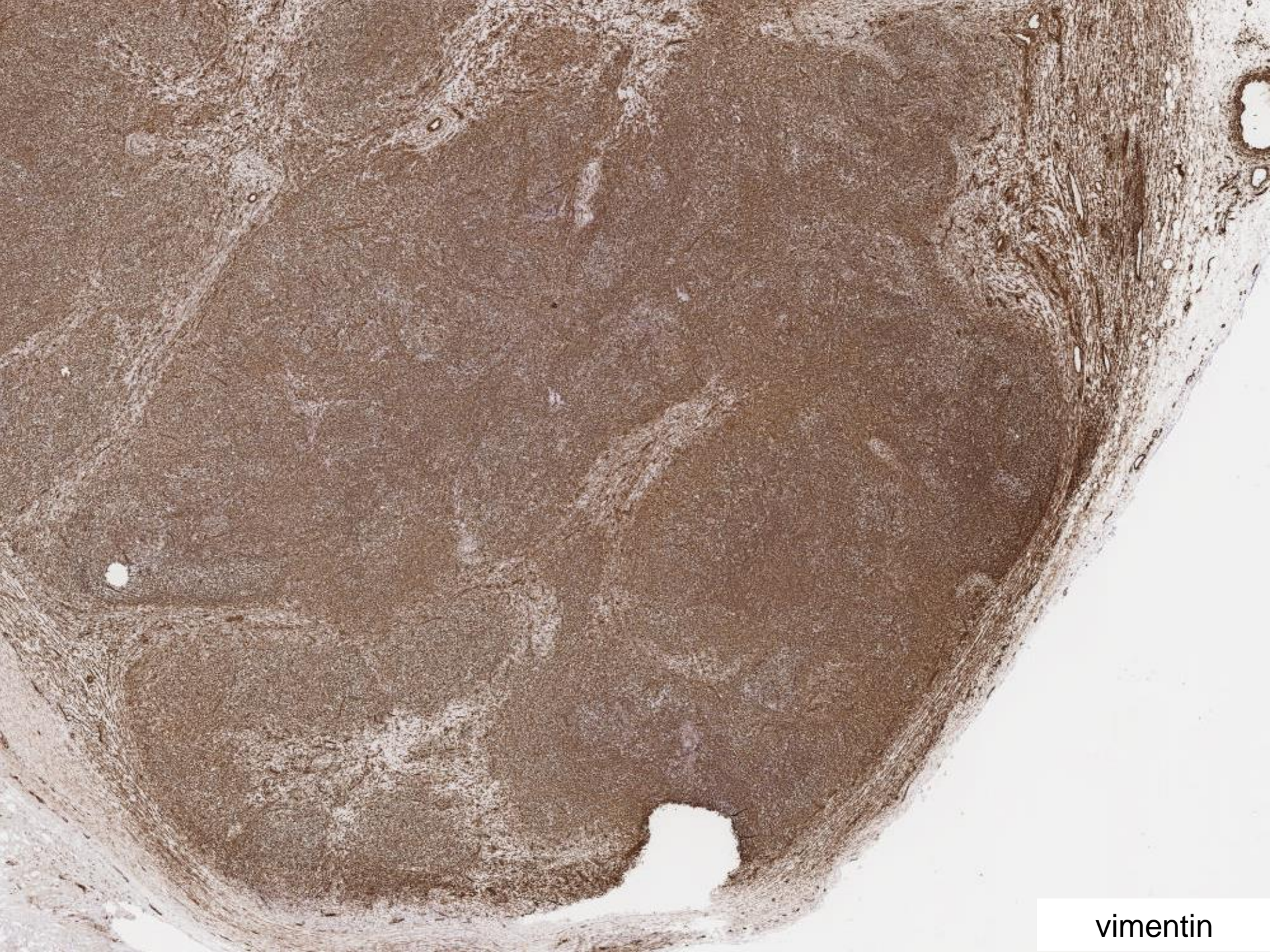
fascin-1




fascin-1



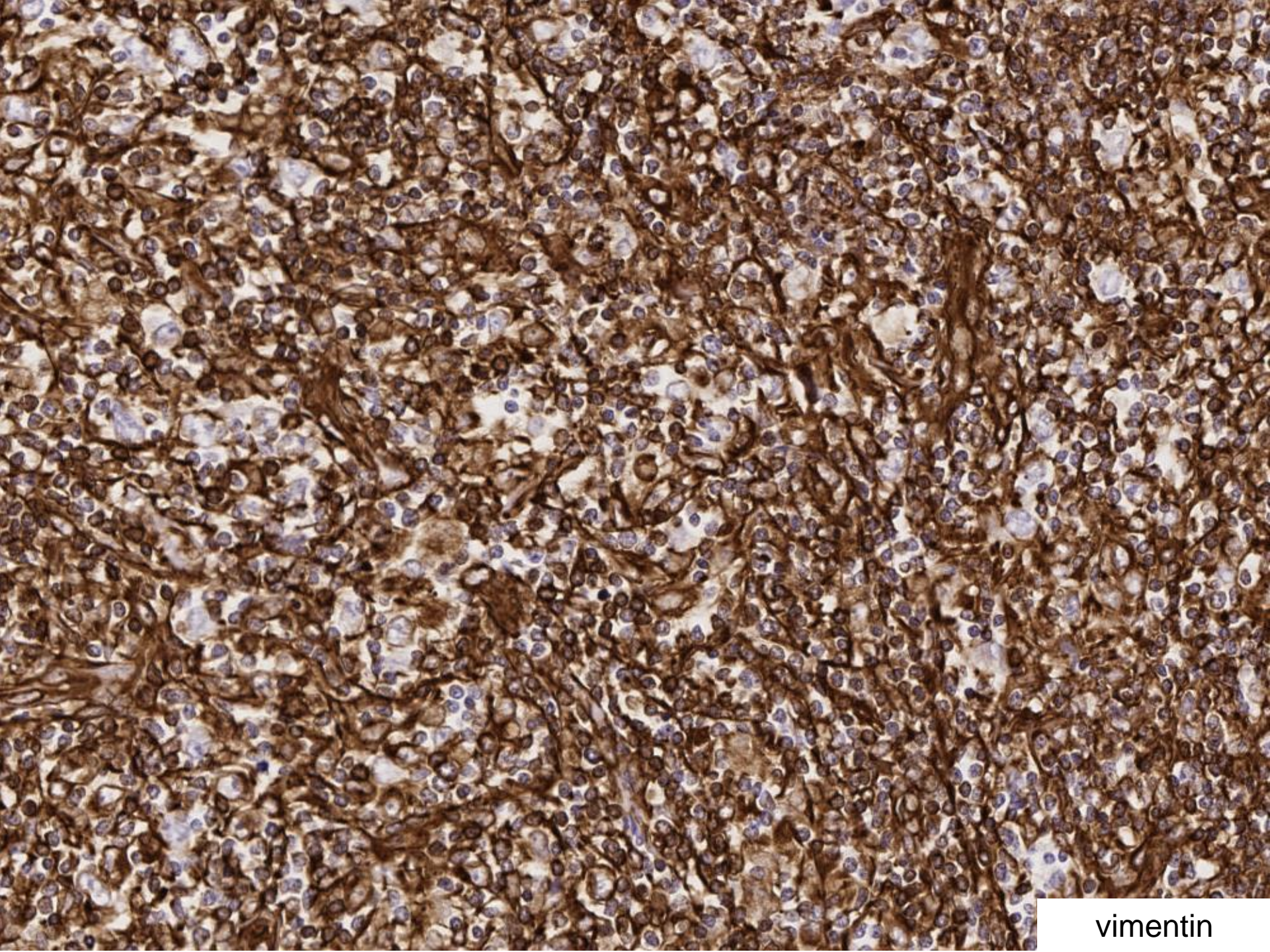
fascin-1



vimentin



vimentin



vimentin

Diagnosis

- c/w nodular sclerosing Hodgkin lymphoma

Large cell IHC/flow cytometry:

- CD15+/CD30+/fascin+
- CD20-/CD5-/CD45-
- No abnormal phenotype identified by flow cytometry
- Consistent with HL